Intermittent myopic shift of 4.0 diopters after implantation of an Artisan iris-supported phakic intraocular lens

Thomas Kohnen, MD, Magdalena Cichocki, MD, Jens Bühren, MD, Martin Baumeister, MD

A 45-year-old man with bilateral high myopia and myopic astigmatism had uneventful implantation of a −10.5 diopters (D) Artisan iris-fixated anterior chamber phakic intraocular lens (PIOL) (Ophtec) in both eyes. In the first days after surgery, uncorrected visual acuity (UCVA) was 20/16 in the right eye and 20/16 in the left; the position of the PIOL was stable. Ten days after surgery, the left eye developed a myopic shift of 4.0 D. Further examination showed that the myopia disappeared when the pupil was medically dilated. After the pupil returned to a natural position, the myopic shift reappeared. Because there were no changes in the subsequent 4 months, we decided to exclavate the IOL, rotate it by 10 degrees, and reenclavate it with less tissue. The myopic shift did not return over the following 20 months, and the UCVA was 20/20. In rare cases, iris-fixated anterior chamber IOLs may induce refractive changes related to effects on the surrounding anatomic structures. This may be corrected by phakic IOL rotation or reenclavation of the phakic IOL with less tissue.

J Cataract Refract Surg 2005; 31:1444–1447 © 2005 ASCRS and ESCRS

Iris-fixated anterior chamber intraocular lenses (IOLs) were introduced in 1978 by Jan Worst as IOLs for aphakia. These IOLs are enclavated in iris tissue for permanent fixation. The principle was adapted for phakic IOLs in 1986 to correct refractive errors, particularly those of higher degree. This report documents an unusual unilateral case of intermittent myopic shift after implantation of an iris-fixated phakic for the correction of high myopia.

Case Report

A healthy, 45-year-old white man whose visual acuity had been corrected with spectacles since he was 4 years of age requested refractive treatment for high myopia. The patient could not tolerate contact lenses. Uncorrected visual acuity (UCVA) was 20/400, and best spectacle-corrected visual acuity (BSCVA) was 20/25 with −10.75 −0.75 × 20 in the right eye (right eye) and 20/20 with −10.0 −1.75 × 165 in the left eye (left eye). Intraocular pressure (IOP) was 17 mm Hg right eye and 15 mm Hg left eye; axial length was 27.06 mm right eye and 27.18 mm left eye. Corneal topography showed regular astigmatism in both eyes. Keratometry-readings were 44.7/98 and 43.6/8 right eye and 44.5/77 and 43.5/167 left eye. Pachymetry revealed 553 μm corneal thickness right eye and 562 μm left eye; scotopic pupil size measured by the Colvard pupillometer (Oasis Medical) was 5.0 mm in both eyes (both eyes). Slitlamp examination and fundoscopy were unremarkable. The patient was educated regarding surgical options to correct his refractive error and signed an informed consent for phakic IOL implantation.

The surgical procedure began with paracenteses at the 1:30 and 11:30 positions after peribulbar anesthesia with lidocaine hydrochloride (Xylocaine 2%) was given. The anterior chamber was then filled with acetylcholine (Myostat) followed by injection of sodium hyaluronate 1% (Healon). A 5.8 mm posterior limbal tunnel incision was made on the steep corneal meridian, followed by implantation of the PIOL (Artisan, Ophtec; −10.5 D, 6.0 mm optic) in the anterior chamber. The phakic PIOL was rotated into

Accepted for publication November 8, 2004.

From the Johann Wolfgang Goethe-University, Department of Ophthalmology, Frankfurt am Main, Germany.

No author has a financial or proprietary interest in any method or material mentioned.

Reprint requests to Thomas Kohnen, MD, Johann Wolfgang Goethe University, Department of Ophthalmology, Theodor-Stern-Kai 7, 60590 Frankfurt am Main, Germany. E-mail: Kohnen@em.uni-frankfurt.de.

Published by Elsevier Inc.

0886-3350/05/$-see front matter
doi:10.1016/j.jcrs.2004.11.056

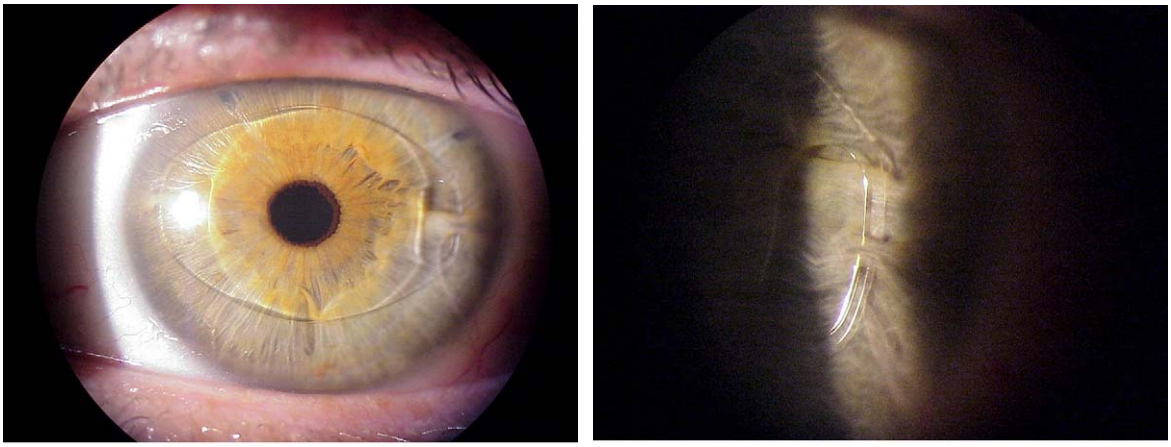

A B

Figure 1. Slitlamp image of the iris-claw PIOL in the left eye in miosis. *A*: One month after primary implantation. *B*: Three months after reenclavation with 10-degree rotation.

the 3 o'clock to 9 o'clock position and enclavated in the iris. After an iridectomy was performed and the ophthalmic viscosurgical device was completely removed, the incision was closed with a running 10-0 nylon suture. Surgery was performed in both eyes by the same surgeon (T.K.) within a 7-day interval.

There were no perioperative or early postoperative complications such as bleeding, inflammation, IOP rise, or IOL dislocation in either eye. The PIOLs were situated horizontally (Figure 1, *A*). The UCVA, refraction, and BSCVA are shown in Table 1.

Postoperative evaluation showed no inflammation in the eyes, and IOP was 20 mm Hg in both eyes measured on day 7. The position of both PIOLs was stable, and the UCVA was 20/25 right eye and 20/20 left eye.

On day 10, the patient presented because of a dramatic decrease in visual acuity in 7 lines left eye. The UCVA had dropped from 20/20 to 20/100, and BSCVA was 20/16 with $-4.0 -0.25 \times 110$ degrees; the right eye was unaffected. The patient did not report trauma or other events. The IOP was 20 mm Hg right eye and 17 mm Hg left eye. Further slitlamp examination showed that the iris was bent slightly backward, and the distance between the PIOL and the natural lens may have been less than in earlier examinations. Otherwise, the results were unremarkable. For further evaluation, 1 drop of tropicamid (Mydriaticum Stulln) was applied in the left eye. Thirty minutes later, the patient reported increase in visual acuity, and UCVA returned to 20/20. In slitlamp examination, the distance between the PIOL and the patient's natural lens appeared to have increased. The situation was unchanged at the following 4 examinations (1, 2, 3, and 4 months). During this period, the patient reported intermittent recurrence of the myopic shift, which was corrected with mydriatic drops.

For further evaluation, wavefront analysis was applied to measure the objective refraction at different pupil sizes induced by tropicamide 2 months after surgery. The linear correlation between these 2 factors is shown in Figure 2 (correlation: $P<.005$, $R^2 = 1.0$, b = 0.7). For assessment of the PIOL position relative to the crystalline lens, Scheimpflug photographs (Figure 3) were also taken using the EAS-1000 anterior segment analysis system by Nidek.[1–3] Other than the distance shift between the PIOL and the crystalline lens in right eye (Table 2), there were no significant changes detected with Scheimpflug photography.

Assuming a connection between iris dynamics and the myopic shift, the PIOL was reenclavated with less tissue (Figure 1, *B*) and reposition by 10 degrees; this procedure was performed through a small, 2.0 mm limbal tunnel incision. The UCVA stabilized between 20/20 and 20/16 and remained so for the following 20 months. The patient is satisfied with the refractive outcome and reports none of the

Table 1. Uncorrected visual acuity (first-line) and BSCVA (second-line) (both eyes) during the study period.

Parameter	Right Eye	Left Eye
Before implantation	20/400	20/400
	20/25 (−10.75 −0.75 × 20)	20/20 (−10.0 −1.75 × 165)
7 days after implantation	20/25	20/20
	20/16 (0.25 −0.75 × 110)	20/16 (−0.25 −0.5 × 130)
10 days after implantation	20/25	20/100
	20/16 (0.25 −0.75 × 110)	20/16 (−4.0 −0.25 × 110)
After reenclavation	20/20	20/16
	20/20 (−0.75 × 94)	20/16 (0.25 −1.0 × 120)

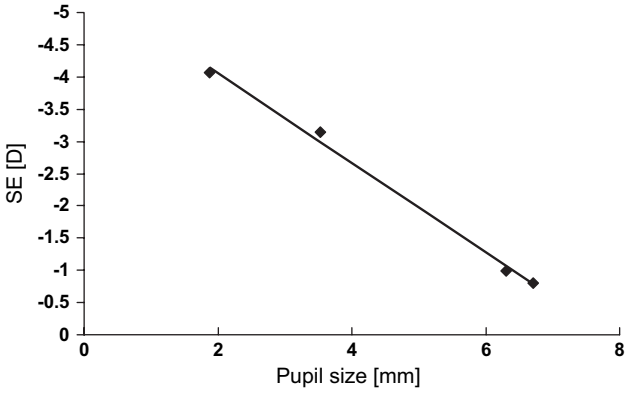

Figure 2. Spherical equivalent (SE) calculated from wavefront analysis at various pupil sizes.

symptoms he experienced during the first postoperative period.

Discussion

In recent years, the literature has shown that the iris-fixated anterior chamber PIOL model has satisfactory and stable refractive outcomes[4–6] and the lens retains a stable intraocular position.[3] The unusual events described in this case do not seem to have been reported.

We note 3 possible explanations for the influence of the PIOL on the intermittent refractive shift:

First, there may have been a shifting distance between the PIOL and the crystalline lens. The measured difference of 0.22 mm before and after cycloplegia in the left eye compared with 0.04 mm in the right eye (Table 2) is significantly higher. Using the Gullstrand formula,[7] the calculation shows, however, that this effect does not induce even 0.05 D of refractive change. According to this formula, if the distance between the PIOL and the natural lens resulted in a myopic shift of 4.0 D, it required an increase of about 18.0 mm. Thus, after reenclavation (Figure 1, *B*) the PIOL in the left eye behaved like that in the right eye (Table 2). This phenomenon may not be completely responsible for the myopic shift, but it likely demonstrates a mechanical connection.

A second possible explanation, based on the idea of mechanical power influencing accommodation processes, is the close anatomy of the iris and the ciliary apparatus. As Helmholtz's[8] theory of accommodation suggests, refractive changes can be naturally induced up to 12.0 D, and it is assumed that in this case, the enclavated haptic of the PIOL triggered a tractive power on the ciliary body. Assuming that the traction of the iris would force the ciliary body to move inward and forward, this would be in the same direction that the ciliary muscle contracts during accommodation.[9–12] Thus, the flexibility of the natural lens increases its refractive power. Underlining this hypothesis, drug-induced cycloplegia (partial cycloplegic effect of tropicamide[13]) would have relaxed the iris and the ciliary muscle, imitating disaccommodation. Moreover, the linear relationship between pupil size and spherical equivalent (SE) (Figure 1) strongly suggests a mechanical effect. In this context, other parameters were also evaluated with Scheimpflug photography, and there was a slightly increased distance between the anterior pole of the crystalline lens and posterior face of the

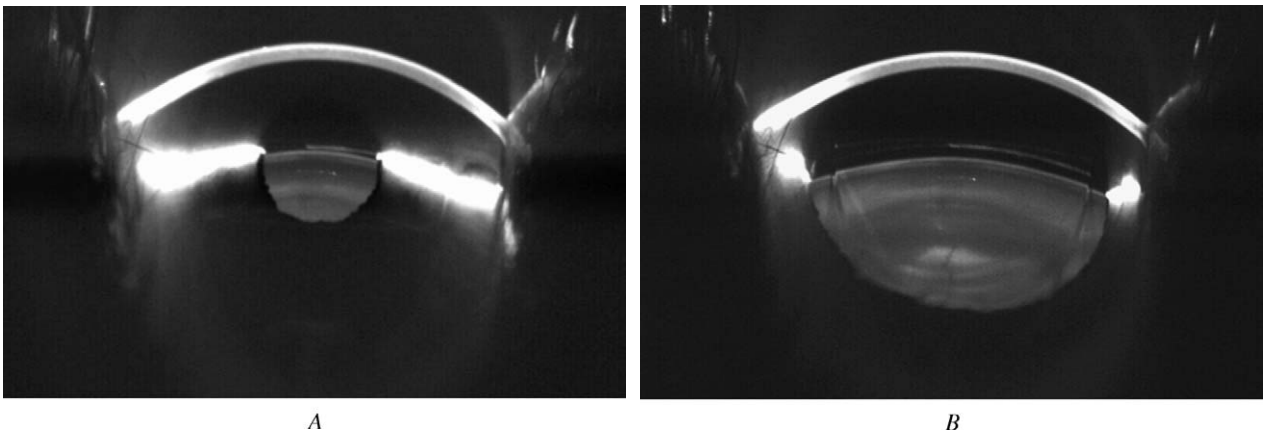

Figure 3. Horizontal and vertical Scheimpflug photography of the left eye 1 month after primary surgery in miosis. The images do not demonstrate major position change of the PIOL as a result of pupil dilatation.

Table 2. Scheimpflug photographic measurement of IOL position—distance (mm) between PIOL and natural lens relative to the visual axis before and after reenclavation.

	OD		OS	
Parameter	**Before Cycloplegia**	**30 min after Cycloplegia**	**Before Cycloplegia**	**30 min after Cycloplegia**
Before reenclavation	0.42	0.38	0.12	0.34
After reenclavation	0.46	0.38	0.48	0.40

OD = right eye; OS = left eye

cornea; although not significant, it may have been an accommodative reaction. Unfortunately, the data cannot provide answers regarding crystalline lens thickness or thus about actual accommodation status.

Finally, and also based on accommodative changes, a third possibility considers the iris as a structure well supplied with blood vessels and nerves that are in anatomic proximity to the ciliary body. An irritation of nerves or vessels could have an impact on the ciliary body and thus might have induced ciliary muscle contraction.

In all 3 hypotheses, the resulting effect of the myopic shift must be connected with the enclavation of the iris-fixated PIOL. Either the haptic enclavated too much tissue so that traction resulted or the enclavated tissue included some nerves or vessels that had an effect. A combination of all 3 mechanisms is also possible.

For these reasons, it appeared necessary to reposition the PIOL in this case. This case report demonstrates that reenclavation and rotation is a possible treatment for intermittent refractive errors after iris-fixated PIOL implantation. It should be noted that either reenclavation or repositioning might have been sufficient. No similar cases seem to have been published, and this has occurred only once. The problem has, however, been presented in oral reports by other surgeons, first by us (T. Kohnen, 2002, ASCRS) and then by others (C. Budo, 2003, Interefract, Paris).

References

1. Sasaki K, Sakamoto Y, Shibata T, et al. Measurement of postoperative intraocular lens tilting and decentration using Scheimpflug images. J Cataract Refract Surg 1989; 15:454–457
2. Baez KA, Orengo S, Gandham S, Spaeth GL. Intraobserver and interobserver reproducibility of the Nidek EAS-1000 anterior eye segment analysis system. Ophthalmic Surg 1992; 23:426–428
3. Baumeister M, Bühren J, Kohnen T. Position of angle-supported, iris-fixated, and ciliary sulcus-implanted myopic phakic intraocular lenses evaluated by Scheimpflug photography. Am J Ophthalmol 2004; 138:723–731
4. Alexander L, John M, Cobb L, et al. U.S. clinical investigation of the Artisan myopia lens for the correction of high myopia in phakic eyes. Report of the results of phases 1 and 2, and interim phase 3. Optometry 2000; 71:630–642
5. Maloney RK, Nguyen LH, John ME. Artisan phakic intraocular lens for myopia: short-term results of a prospective, multicenter study; the Artisan Lens Study Group. Ophthalmology 2002; 109:1631–1641
6. Menezo JL, Peris-Martínez C, Cisneros AL, Martínez-Costa R. Phakic intraocular lenses to correct high myopia: Adatomed, Staar, and Artisan. J Cataract Refract Surg 2004; 30:33–44
7. Gullstrand A. Der Mechanismus der Akkommodation. In: Helmholtz H, ed, Handbuch der Physiologischen Optik, 3d ed. Hamburg; Leipzig, Leopold Voss, 1909; 327–353
8. Helmholtz H. Ueber die Accommodation des Auges. Albrecht von Graefes Arch Ophthalmol 1855; 1(2):1–74
9. Bacskulin A, Bergmann U, Horoczi Z, Guthoff R. Kontinuierliche ultraschallbiomikroskopische Darstellung der akkommodativen Veränderung des humanen Ziliarkörpers. Klin Monatsbl Augenheilkd 1995; 207: 247–252
10. Bacskulin A, Gast R, Bergmann U, Guthoff R. Ultraschallbiomikroskopische Darstellung der akkommodativen Konfigurationsänderungen des presbyopen Ziliarkörpers. Ophthalmologe 1996; 93:199–203
11. Bacskulin A, Martin H, Kundt G, et al. Analyse der Dynamik des Ziliarmuskels während der Akkommodation. Ophthalmologe 2000; 97:855–859
12. Stachs O, Martin H, Kirchhoff A, et al. Monitoring accommodative ciliary muscle function using three-dimensional ultrasound. Graefes Arch Clin Exp Ophthalmol 2002; 240:906–912
13. Mirshahi A, Kohnen T. Acute psychotic reaction caused by topical cyclopentolate use for cycloplegic refraction before refractive surgery; case report and review of the literature. J Cataract Refract Surg 2003; 29:1026–1030