Metaanalysis of cataract development after phakic intraocular lens surgery

Li-Ju Chen, MD, Yun-Jau Chang, MD, Jonathan C. Kuo, MD, Rama Rajagopal, FRCS Ed, Dimitri T. Azar, MD

We performed a systematic literature review to determine the incidence of and predisposing factors for cataract after phakic intraocular lens (pIOL) implantation. Of the 6338 eyes reported, 4.35% were noted to have new-onset or preexisting progressive cataract. The incidence of cataract formation was 1.29%, 1.11%, and 9.60% with anterior chamber, iris-fixated, and posterior chamber (PC) pIOLs, respectively. In the PC pIOL group, early cataract formation was related to surgical trauma and late-onset cataract was related to IOL–crystalline lens contact. Analysis of cataract progression in eyes with preexisting cataract showed a progression rate of 29.5% after pIOL surgery. These results suggest that cataract formation is most likely to occur after PC pIOL implantation. Patients with preexisting progressive cataract should be informed about the possibility of cataract progression and possible need for cataract surgery after pIOL implantation. Cataract surgical intervention resulted in restoration of visual acuity.

J Cataract Refract Surg 2008; 34:1181–1200 © 2008 ASCRS and ESCRS

Phakic intraocular lenses (pIOLs) are used to treat myopia, and recently, hyperopia. Several reports confirm the efficacy and predictability of the pIOLs,[1–4] although their long-term safety has not been established.[5–8] Reported complications include corneal decompensation,[9,10] pupillary ovalization,[11,12] pupillary block glaucoma,[6,13,14] retinal detachment (RD),[9,15,16] and endophthalmitis.[17]

The history of pIOLs dates back to Strampelli,[18] who in 1953 implanted minus-powered pIOLs in the anterior chamber (AC) to correct high myopia. Due to severe complications resulting from poor quality, rigidity, and inappropriate length, a high percentage of earlier pIOLs had to be explanted.[19] Despite the well-known setbacks of Strampelli, Barraquer, Choyce, and Momose, the idea of built-in glasses or contact lenses persisted.[20] Since the mid-1980s, progress in manufacturing and surgical techniques has led to the development of 3 major types of pIOLs of modern design: AC angle-fixated pIOLs (AC pIOLs); AC iris-fixated pIOLs (IF pIOLs); and posterior chamber (PC) sulcus-fixated pIOLs (PC pIOLs).[21,22]

Designed by Baikoff and Joly,[23] modern AC pIOLs are modified Kelman Multiflex-style IOLs[21] in which the thickness and size of the optic and the profile of the haptics were altered to minimize corneal endothelial loss, pupillary ovalization, glare, and halos. The evolution of generations of Baikoff IOLs included the earlier prototypes ZB and ZB5M and the current Nu-Vita. Other variations include ZSAL-4 and Phakic 6 IOLs.[24–27]

Iris-fixated pIOLs were initially developed in 1986 as the Worst-Fechner biconcave iris-claw IOL for the correction of myopia based on previous successful experiences in aphakic patients.[28,29] Later, the IOL was modified into the Worst myopia claw IOL, which had a larger convex–concave optic to decrease corneal endothelial damage, glare, and halos.[30] In 1998, the name was changed to the Artisan IOL (distributed by Ophtec) without changing the design.[9,31] The

From the Department of Ophthalmology and Visual Sciences (Azar), Illinois Eye and Ear Infirmary, University of Illinois at Chicago, Chicago, Illinois; the Corneal and Refractive Surgery Service (Chen, Kuo, Rajagopal, Azar), Massachusetts Eye and Ear Infirmary, and the Schepens Eye Research Institute, Harvard Medical School, Boston, Massachusetts, and; Taipei City Hospital Heping Branch (Chen) and the Graduate Institute of Health Care Organization Administration (Chang), College of Public Health, National Taiwan University, Taipei, Taiwan.

No author has a financial or proprietary interest in any material or method mentioned.

Supported by National Institute of Health Grant EY10101 (Dr. Azar) and the University of Illinois Eye Fund (Dr. Azar).

Corresponding author: Dimitri T. Azar, MD, Professor and Department Head, Department of Ophthalmology and Visual Sciences, Illinois Eye and Ear Infirmary, University of Illinois at Chicago, 1855 West Taylor Street, Chicago, Illinois 60612, USA. E-mail: dazar@uic.edu.

Published by Elsevier Inc.

doi:10.1016/j.jcrs.2008.03.029

Verisyse IOL, the same IOL as the Artisan but with a different brand name (distributed by Advanced Medical Optics), is used exclusively in North America and Japan. In 2004, the Artisan/Verisyse IOL was the first pIOL to receive U.S. Food and Drug Administration (FDA) approval.[32] Because of its firm fixation to the iris stroma, rotation of the iris-claw IOL is less likely. Hence, there are more and more studies of toric Artisan/Verisyse IOLs to correct astigmatism.[33–37] Recent progress in the foldable model (Artiflex/Veriflex) to reduce incision size and surgically induced astigmatism is underway.[25,38,39]

Posterior chamber pIOLs were first introduced in 1986.[40] The original design had a collar-button configuration with the optic located in the AC and the haptics behind the iris.[41] Despite additional modifications in the plate silicone IOL of the Russian design and the Chiron-Adatomed IOL, these silicone IOLs were discontinued due to high cataractogenesis. More recent design modifications allowed the use of a foldable plate convex–concave IOL made of porcine collagen hydroxyethyl methacrylate copolymer (less than 0.1% collagen).[41] This sulcus-fixated Staar Collamer Implantable Contact Lens vaults over the anterior lens capsule and provides space for the aqueous.[42] To avoid confusion with corneal contact lenses, as requested by the FDA, the well-recognized name "Implantable Contact Lens" was changed to the name "Implantable Collamer Lens (ICL)" to retain the ICL acronym.[43] The current Version Four model, also known as the Visian ICL,[44] was approved by the FDA in 2005. A toric ICL for spherocylindrical correction is recently under investigation.[44] A new foldable phakic refractive lens (PRL) made of medical-grade silicone is designed with its haptics resting on the zonule without riding on the sulcus.[45–48] However, because late complications such as zonular dehiscence and subluxation or dislocation of the PRL into the vitreous cavity have not yet been elucidated, some authors have stopped implanting the PRL for the present time.[49,50]

Cataract development has been noted after AC, IF, and PC pIOL implantation. Several factors may be involved including surgical trauma,[51,52] age,[53,54] pIOL–crystalline lens touch (including intermittent contact during accommodation),[42,55] myopia,[53,54] biocompatibility of the pIOL,[7] change in the blood–aqueous barrier (BAB),[56] and chronic subclinical inflammation.[7]

Comparative analyses of the incidence, type, and visual outcomes of cataract formation after implantation of different types of pIOL are lacking, and the incidence of cataract after PC pIOL implantation has varied within a wide range. We present the results of a retrospective analysis of reports of pIOL surgery to determine the location (type), incidence, and outcomes of new-onset cataract and progressive cataract and to explore predisposing factors in and possible mechanisms of cataract formation.

MATERIALS AND METHODS

Study Design

Published journal articles were considered as the elements of study, and a pertinent literature search was performed in 4 stages.

Stage 1 (Unique Citations) A Medline (National Library of Medicine, Bethesda, Maryland, USA) search from 1966 to December 2006 was performed to identify all articles describing pIOLs. The terms *intraocular lens* (IOL) and *intraocular lens implantation* from the Medical Subject Headings (MeSH) and the text word *phakic* were used for a broad and sensitive search. Six other searches were performed to look for additional articles (using the text words *phakic* and *lens*, the text words *phakic* and *IOL*, the text words *Artisan lens*, the text words *Verisyse lens*, the text words *Collamer lens*, and the text words *Implantable Contact Lens*).

Stage 2 (Article Retrieval) All abstracts from the Medline searches were scrutinized to identify articles that were pertinent to clinical results, surgical techniques, or complications of AC, IF, or PC pIOLs. Only journal articles published in English were included. Copies of the articles were obtained, and their bibliographies were searched manually for additional articles published in peer-reviewed journals.

Stage 3 (Article Inclusion) Complete articles were reviewed to identify those that reported original clinical data or complication(s) of pIOL implantation. Only articles using microsurgical techniques to implant the 3 major modern designs of pIOLs into phakic eyes were included in the study. Of papers covering previously published cases, those adding new case(s) or up-to-date results were included. Care was taken not to double-calculate data of previously published cases.

Stage 4 (Article Exclusion) Complications reported as selected case reports or pIOL pathology reports that could not be linked to a clinical series, meaning an incidence could not be calculated, were excluded from the analysis. Articles on cataract complications after pIOL implantation in which exact numbers of cataracts were not known were excluded. Partially duplicated series in which the exact patient population could not be clearly differentiated from former published populations were also excluded. Small case studies (subject enrollment <5) that could not be correlated with sequentially published studies were excluded.

Data Abstractions and Analysis

A meticulous and systematic review of the complete articles was performed. All appropriate information regarding aspects of cataracts after pIOL implantation was abstracted on 3 spreadsheet programs (Microsoft Excel, Microsoft Corp.) relating to the mutually exclusive groups of AC pIOLs, IF pIOLs, and PC pIOLs. Patient population characteristics were recorded. Complications and their treatment were noted, including removal, replacement, and other reoperations. In the circumstance of reoperation for treating

complications other than cataract, if an eye developed cataract after the reoperation, so that cataract formation could not be primarily linked to pIOL surgery itself, the eye was expelled from the incidence of cataract calculation. To determine the incidence of cataract formation, the sum of new-onset, preexisting progressive cataracts was divided by the total number of pIOLs. Preexisting nonprogressive cataracts were excluded from these calculations.

Literature Analysis

The literature search identified 818 unique citations (Stage 1). In Stage 2, 310 articles were retrieved, 229 of which satisfied Stage 3 criteria; 123 articles eventually satisfied Stage 4 standards and were included in the study. There were 24 articles on AC pIOLs,[4,11,12,15,23,26,27,53,56–71] 5 of which described previously published cases.[15,53,62,63,69] There were 50 articles on IF pIOLs,[3,6,8–10,28,30,31,33,35–39,72–107] 14 of which covered formerly published cases.[8,9,73–75,89–96,99] Of the 49 articles on PC pIOLs,[1,2,7,42,43,45–48,50–52,54,55,108–142] 10 depicted previously published cases.[43,126–130,133,135,136,141] The 3 articles that discussed both AC pIOLs and IF pIOLs,[8,72,73] the 2 articles that discussed both IF pIOLs and PC pIOLs,[74,75] and the 1 article that discussed all 3 groups of pIOLs[76] were placed in the IF pIOL group. Although most studies excluded patients with preexisting cataract, some included patients with other ocular pathologies.[35,54,64,128,141]

Subgroup Analysis of Angle-Fixated Anterior Chamber Phakic Intraocular Lenses

There were 2 reports of angle-fixated AC pIOLs in both hyperopic and myopic eyes,[27,69] 1 report in hyperopic eyes,[68] and 2 reports in presbyopic eyes[26,27]; the remaining reports were in myopic eyes. Two studies were of bioptics.[65,70]

Preoperative Characteristics The review showed 1161 eyes of at least 732 patients that had implantation of an AC pIOL. Of the 547 patients for whom data were available, the mean age at implantation was 35.95 years (range 20 to 70 years). After analysis, 37.71% of the patients were men. The mean preoperative spherical equivalent (SE) was −15.02 diopters (D) (range −4.50 to −30.00 D) in 792 myopic eyes and +4.89 D (range +1.25 to +10.50 D) in 70 hyperopic eyes. The mean SE in the myopic bioptics group was −14.61 D (range −8.25 to −30.0 D) in 67 eyes. The mean follow-up was 26.98 months (range 1 to 91 months) in 1053 eyes.

Intraocular Lens Models Used Of 1161 eyes, 72 received a first-generation ZB IOL; 465, the ZB5M (including 80 ZB5MF); 492, the ZSAL-4; 12, the Phakic 6H; 31, the NuVita, 55, the Newlife/Vivarte Presbyopic; and 34, the AMO multifocal pIOL prototype.

Postoperative Complications The complications (number of eyes) were halos and/or glare (294); pupil ovalization (146); intraocular pressure (IOP) increase (129); IOL rotation (56); uveitis (41); decentration (39); iris atrophy (13); RD (10); corneal edema (9); secondary refractive procedure for residual refractive error (6); inflammatory deposits on IOL (5); eye pain (5); cystic wound or wound leak (4); pigment deposits on IOL (4); incorrect power calculation (2); postoperative atonic pupil (Urrets-Zavalia syndrome) (2); macular hemorrhage (2); giant papillary conjunctivitis due to suture exposure (1); endothelial pigment dispersion (1); excessive vaulting (1); loop foot in iridectomy site (1); and diplopia due to large iridectomy (1) (Figure 1, *A*). One eye developed RD after pIOL implantation and had 2 RD surgeries; the pIOL was explanted during the second RD surgery. Forty-five eyes required reoperations for complications other than cataract (Figure 2, *A*).

Category, Type, Incidence, and Outcomes of Cataracts The review showed 16 eyes with cataract (15 new onset, 1 preexisting nonprogressive) in 6 studies. Of the 15 new-onset cataracts, 9 were nuclear sclerotic (NS), 3 were nonprogressive posterior subcapsular cataract (PSC), 2 were nonprogressive anterior subcapsular cataract (ASC), and 1 was ASC and PSC.

The incidence of cataract formation with AC pIOLs was 1.29%. The incidence with the ZB5M and ZSAL-4 pIOL models was 2.58% and 0.61%, respectively. No cataracts were reported in eyes with the ZB, NuVita, Phakic 6H, Newlife/Vivarte Presbyopic, or AMO multifocal prototype pIOL. The mean time from pIOL implantation to development of new-onset cataract was 33.10 months.

Ten (9 NS, 1 ASC and PSC) of the 15 new-onset cataracts required surgery. All eyes had successful and uneventful cataract surgery with removal of the AC pIOL and implantation of PC IOL in the bag.

Subgroup Analysis of Iris-Fixated Anterior Chamber Phakic Intraocular Lenses

There were 4 reports of IF AC pIOLs in both hyperopic and myopic eyes[31,33,35,101] and 5 reports in hyperopic eyes[36,85,87,98,103]; the other IF AC pIOLs were in myopic eyes. In 2 reports, 1 eye of a patient received laser in situ keratomileusis (LASIK) and the other eye received an Artisan lens;[81,86] there were also 3 studies of bioptics.[79,84,103]

Preoperative Characteristics The review showed 2781 eyes of at least 1729 patients had implantation of an IF pIOL. Of the 1489 patients for whom data were available, the mean age was 35.47 years (range 17 to 67 years). After analysis, 41.95% of patients were men. The mean preoperative SE for the Worst-Fechner biconcave IOL was −14.51 D (range −5.00 to −31.75 D) in 225 eyes. The mean preoperative SE for the Artisan IOL eyes was −12.89 D (range −1.50 to −29.00 D) in 1637 myopic eyes and +6.39 D (range 0.00 to +18.00 D) in 277 hyperopic eyes. The mean preoperative SE for the Artiflex IOL was −8.97 D (range −4.00 to −13.00 D) in 72 eyes. The mean SE in the myopic bioptics group was −18.34 D (range −16.00 to −23.00 D) in 34 eyes. The mean SE in the hyperopic bioptics group was +7.39 D (range +5.25 to +9.75 D) in 39 eyes. The mean follow-up was 32.76 months (0.25 to 158 months) in 2165 eyes.

Intraocular Lens Models Used Of the 2781 eyes, 318 had a first-generation Worst-Fechner biconcave iris-claw IOL, 2075 had an Artisan/Verisyse IOL for myopia (including the Worst myopia claw IOL and the Artisan toric IOL for myopia), 316 had an Artisan/Verisyse IOL for hyperopia (including the Artisan toric IOL for hyperopia), and 72 had an Artiflex IOL.

Postoperative Complications The complications (number of eyes) were halos and/or glare (244); uveitis (125); IOP increase (118); iris atrophy (65); pigment deposits on IOL (48); corneal edema (47); decentration (46); cystic wound or wound leak (40); pupil ovalization (40); pigment dispersion

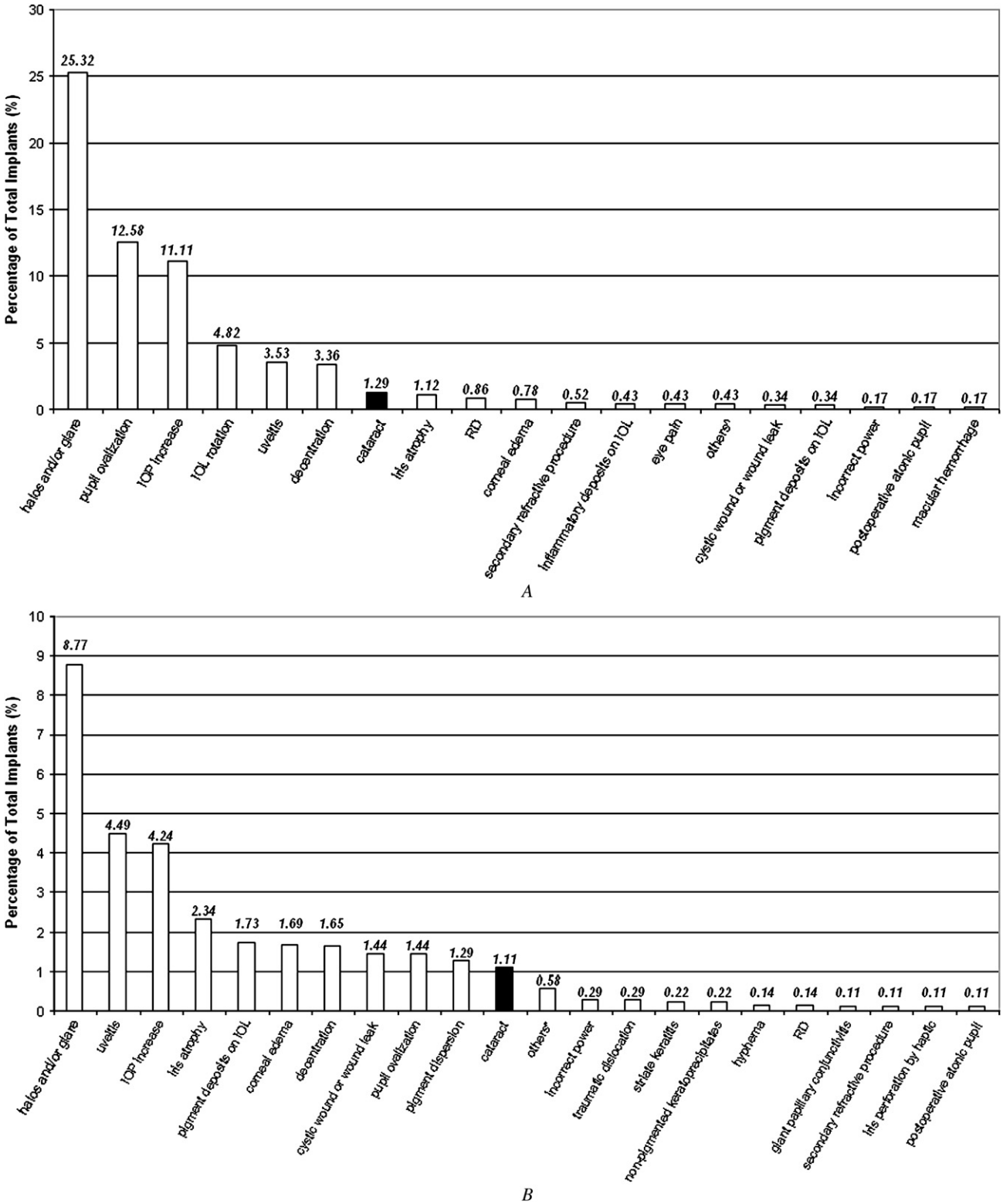

Figure 1. Bar charts show the complications after 1161 AC pIOL implantations (*A*), 2781 IF pIOL implantations (*B*), and 2396 PC pIOL implantations (*C*). Cataract formation was most likely to occur after PC pIOL surgery. ^Includes 1 eye with giant papillary conjunctivitis, 1 with endothelial pigment dispersion, 1 with excessive vaulting, 1 with loop foot in iridectomy site, and 1 with diplopia. *Includes 7 eyes with IOL replacement (reason not clear), 2 with pIOL removal due to inability to observe endothelium, 2 with diplopia, 1 with pIOL removal due to frequent eye rubbing, 1 with wound infection, 1 with a damaged haptic, 1 with iris prolapse, and 1 with retinitis centralis serosa. **Includes 2 eyes with IOL replacement (reason not clear), 1 with iris prolapse, 1 with pupil ovalization, 1 with pupillary entrapment of IOL, 1 with a broken lens, 1 with removal due to aberrant ciliary body anatomy, 1 with progressive dry macular degeneration, and 1 with retinal hole.

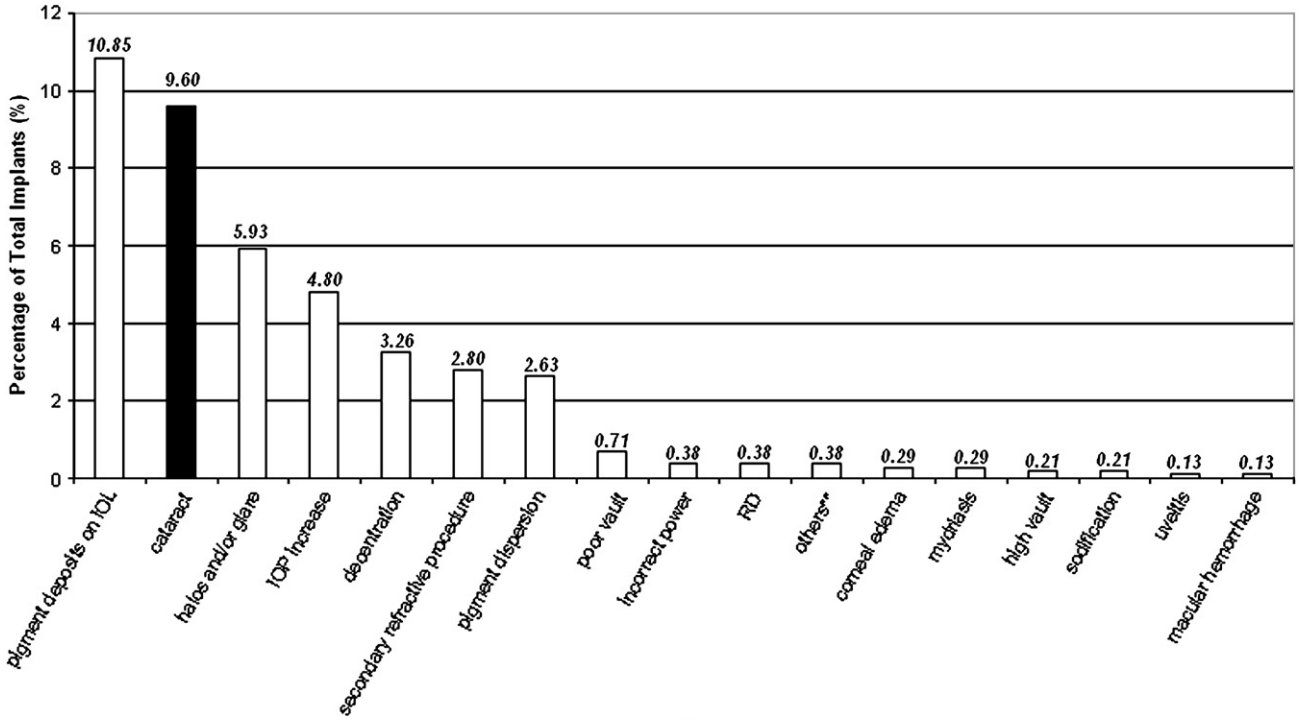

C

Figure 1. (Cont.)

(36); incorrect power calculation (8); traumatic dislocation (8); IOL replacement, with the reason not clear (7); striate keratitis (6); nonpigmented keratoprecipitates (6); hyphema (4); RD (4); giant papillary conjunctivitis due to suture exposure (3); secondary refractive procedure for residual refractive error (3); iris perforation by the claw haptic (3); postoperative atonic pupil (3); IOL removal due to ocular nystagmus and inability to observe endothelium (2); diplopia (2); IOL removal due to frequent eye rubbing (1); wound infection (1); damaged haptic (1); iris prolapse (1); retinitis centralis serosa (1) (Figure 1, *B*). Three eyes received 2 reoperations. One eye developed pigment dispersion and had pIOL removal with perioperative cleaning of the anterior lens capsule. Subsequent cataract extraction was performed 2 months after pIOL explantation. Two eyes of a patient developed uveitis, corneal edema, and IOP elevation and had 2 reoperations in both eyes (pIOL removal, lens extraction, trabeculectomy, and later corneal transplantation, keratoprosthesis surgery). Ninety-one eyes required reoperations for complications other than cataract (Figure 2, *B*).

Category, Type, Incidence, and Outcomes of Cataracts The review showed 41 eyes with cataract (20 new onset, 11 preexisting progressive, and 10 preexisting nonprogressive) in 15 studies. Of the 20 new-onset cataracts, 10 were NS, 8 were cortical vacuoles, and 1 was ASC; the data for 1 eye were not clear. Of the 11 preexisting progressive cataracts, 5 were NS and 4 were PSC; the data for 2 eyes were not clear. In 10 patients, preexisting cataracts were nonprogressive (4 NS, 2 cortical opacities, 2 PSC, and 2 data not clear).

The incidence of cataract formation with IF pIOLs was 1.11%. The incidence with the Worst-Fechner biconcave, myopic Artisan/Verisyse, and hyperopic Artisan/Verisyse IOLs was 2.20%, 1.11%, and 0.32%, respectively. No cataracts were reported with the Artiflex model. The mean time from pIOL implantation to development of new-onset cataract was 37.65 months.

Ten of the 20 (10 NS) new-onset cataracts required surgery, as did 6 (4 PSC, 2 NS) of the 11 preexisting progressive cataracts. All eyes had uneventful pIOL explantation and cataract surgery.

Subgroup Analysis of Posterior Chamber Phakic Intraocular Lenses

There were 9 reports of PC pIOLs in both hyperopic and myopic eyes[45,52,110,113,120,121,134,140,141] and 3 in hyperopic eyes[2,47,114]; the rest were in myopic eyes. Two groups of pediatric patients had IOL implantation,[119,130] and 3 groups had the bioptics technique.[116,117,124]

Preoperative Characteristics The review showed 2396 eyes of at least 1210 patients had PC pIOL implantation. Of the 1064 patients for whom data were available, the mean age was 35.47 years (range 3 to 64 years). After analysis, 40.92% of the patients were men. The mean preoperative SE was −13.21 D (range −3.00 to −39.60 D) in 1988 myopic eyes and +6.28 D (range +2.25 to +11.75 D) in 181 hyperopic eyes. The mean SE in the bioptics group was −20.56 D (range −7.75 to −35.00 D) in 136 eyes. The mean follow-up time was 19.23 months (0.25 to 72.00 months) in 2135 eyes.

Intraocular Lens Models Used Forty-two eyes had implantation of a plate silicone IOL of the Russian design (Fyodorov), 226 eyes of a Chiron-Adatomed IOL, and 1933 eyes of a Staar Collamer ICL (218 V2 or earlier models, 249 V3

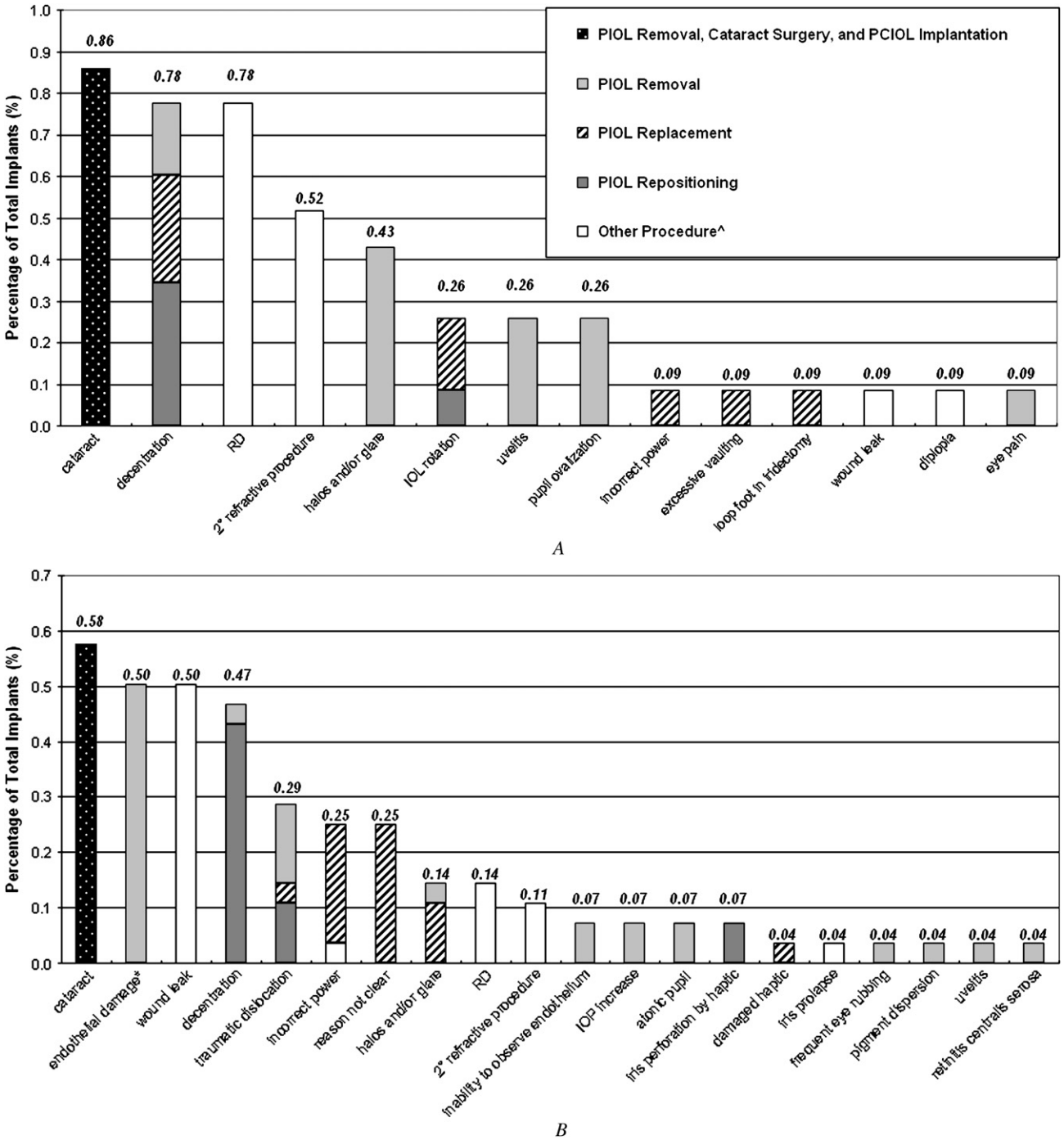

Figure 2. Bar charts show the etiology of reoperation after 1161 AC pIOL implantations (*A*), 2781 IF pIOL implantations (*B*), and 2396 PC pIOL implantations (*C*). The most common cause of pIOL explantation in all 3 groups was cataract. ^Includes keratorefractive surgery, suture, repair, paracentesis, AC irrigation, trabeculectomy, surgical iridectomy, and RD surgery. *Includes 5 eyes that had corneal transplantation (2° = secondary; PIOL = phakic IOL). (Eyes that received more than 2 reoperations are not included in this figure; see text for details.)

models, 877 V4 models, and 589 design not specified). One hundred ninety-five eyes had implantation of a PRL (59 PRL100, 58 PRL101, 25 PRL 200, and 53 designs not specified).

Postoperative Complications The complications (number of eyes) were pigment deposits on IOL (260); halos and/or glare (142); IOP increase (115); decentration (78); secondary refractive procedure for residual refractive error (67); pigment dispersion (63); poor vault (17); incorrect power calculation (9); RD, including 1 giant retinal tear after trauma (9); corneal edema (7); mydriasis (7); high vault (5); white plaques on the anterior surface of natural lens (sodification)

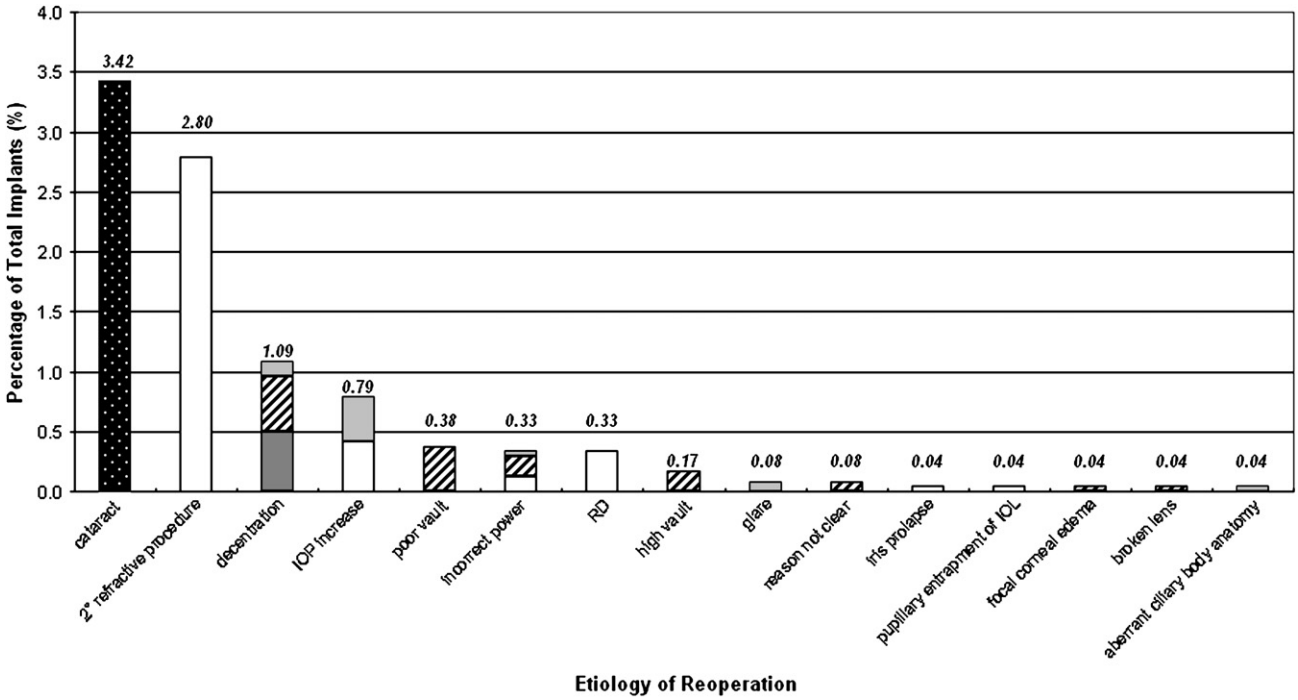

C

Figure 2. (Cont.)

due to incomplete ophthalmic viscosurgical device (OVD) removal (5); uveitis (3); macular hemorrhage (3); IOL replacement, with the reason not clear (2); iris prolapse (1); pupil ovalization (1); pupillary entrapment of the IOL (1); broken IOL (1); IOL removal due to aberrant ciliary body anatomy (1); progression of dry macular degeneration (1); retinal hole (1) (Figure 1, *C*).

Seven eyes had 2 or more reoperation as follows: 2 eyes, decentration–recentration and exchange; 1 eye, incorrect power and poor vault (LASIK), pIOL replacement, and removal; 1 eye, pupillary block glaucoma (immediate surgical iridectomy and later pIOL removal combined with subsequent cataract extraction with PC IOL implantation); 1 eye, neovascular glaucoma (2 trabeculectomies) and pIOL removal combined with phacoemulsification of the clear lens with PC IOL implantation; 1 eye, malignant glaucoma (surgical iridectomy), pars plana vitrectomy (PPV), lensectomy, pIOL removal, and later PC IOL implantation; 1 eye, giant retinal tear after trauma (PPV, lensectomy, pIOL removal, and PPV again with silicone oil injection). One hundred fifty-seven eyes required reoperations for complications other than cataract (Figure 2, *C*).

Category, Type, Incidence, and Outcomes of Cataracts The review showed 262 eyes with cataract (223 new onset, including 6 eyes developing an ASC after intraoperative surgical iridectomy or neodymium:YAG [Nd:YAG] iridotomy; 7 preexisting progressive; and 32 preexisting nonprogressive) in 35 studies.

There were 223 new-onset cataracts (195 ASC, 5 NS, 4 ASC and cortical opacities, 3 ASC and NS, 3 anterior cortical opacities, and 13 eyes data not clear). Seven eyes had preexisting progressive cataract (3 NS, 2 cortical opacities, 1 ASC and PSC, and 1 ASC); 32 eyes had preexisting nonprogressive cataracts (14 cortical opacities, 6 NS, 4 ASCs, 3 PSC, 2 ASC and PSC, and 3 eyes data not clear).

The incidence of cataract with PC pIOLs was 9.60%. The incidence in the Chiron-Adatomed, Staar Collamer, and PRL groups was 25.66%, 8.48%, and 3.59%, respectively. The incidence of cataract formation with the hyperopic Staar Collamer ICL was 11.05%. Only 2 papers evaluated the Russian-design pIOLs, and only 1 preexisting progressive cataract was reported. This IOL was taken off the market because of high cataractogenesis. Due to the paucity of reported information, no attempt was made to calculate the incidence of cataract formation of this IOL model.

In the 99 eyes with new-onset cataract in the Staar Collamer group for which data were available, the mean time of development of cataract from pIOL surgery was 16.67 months (range 1 day to 44 months). In the 42 eyes with new-onset cataract in the Chiron-Adatomed IOL group for which data were available, the mean time from implantation to appearance of cataract was 11.96 months (range 1 week to 24 months). Of the 7 eyes with new-onset cataract in the PRL group for which data were available, 6 developed cataract immediately after surgery due to surgical trauma and the other eye developed cataract 24 months after pIOL surgery.

Where data were available, the mean lapsed time between pIOL implantation and cataract surgery was 22.93 months (16 eyes) in the Staar Collamer ICL group and 17.15 months (16 eyes) in the Chiron-Adatomed IOL group. Seventy-six eyes with new-onset cataract (57 ASC, 3 ASC and NS, 3 ASC and cortical opacities, 3 NS, and 10 eyes data not available) and 6 eyes with preexisting progressive cataract (3 NS, 1 ASC and PSC, 1 ASC, 1 cortical opacity) had cataract surgery. All eyes had uneventful pIOL removal and cataract surgery.

Overall Characteristics

The review showed that primary pIOLs (1161 AC, 2781 IF, and 2396 PC) were implanted in 6338 eyes, of which 258 had new-onset cataract (15, 20, and 223, respectively) and 61 had preexisting cataract (1, 21, and 39, respectively). In terms of preexisting cataract, 43 were nonprogressive (1, 10, and 32, respectively) and 18 (11 IF, 7 PC) were progressive (Figure 3). According to our definition, the overall incidence of cataract formation was 4.35%. The incidence of cataract formation was 1.29%, 1.11%, and 9.60% in the AC pIOL, IF pIOL, and PC pIOL groups, respectively. The incidence of types of cataract formation with various IOL models is shown in Figure 4.

Among the new-onset cataracts, NS was the predominant type in the AC group (9, 60.00%) and IF group (10, 50.00%) whereas ASC was the predominant type in the PC group (202, 90.58%). Most new-onset ASCs in the PC group were nonprogressive or slowly progressive, and 63 eyes (31.19%) required surgery. All new-onset NS cataracts in each group were visually significant, and all eyes with new-onset NS cataract in the AC and IF groups required surgery. Operations were performed in 12 eyes (19.67%) with preexisting cataract.

The most common complications after pIOL implantation in the AC group and IF group were halos and/or glare (294 eyes and 244 eyes, respectively) and pigment deposits on the IOLs in the PC group (260 eyes) (Figure 1). The most common reason for pIOL explantation in all pIOL groups was cataract formation (Figure 2).

DISCUSSION

Contemporary surgical techniques to correct refractive errors include keratorefractive surgery, clear lens extraction, and pIOL implantation. Each option has its advantages and disadvantages.

Keratorefractive surgery avoids the risks of open-globe surgery, but it is not without limitations. Important shortcomings are irreversibility (except intrastromal corneal ring segments), dependence on wound healing, restrictions based on corneal thickness, induction of higher-order optical aberrations,

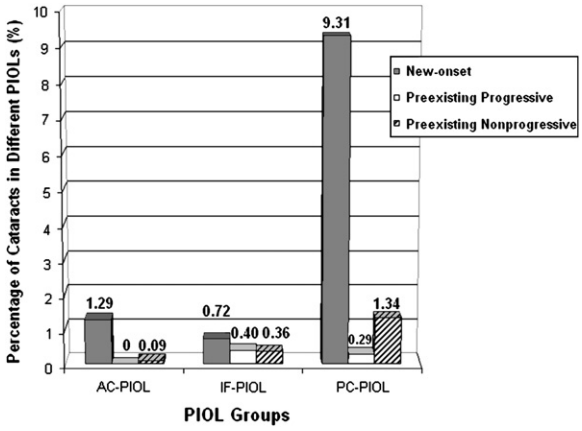

Figure 3. Categories of cataract in the 3 pIOLs groups. New-onset cataracts after pIOL surgery were most evident in the PC pIOL group (PIOL = phakic IOL).

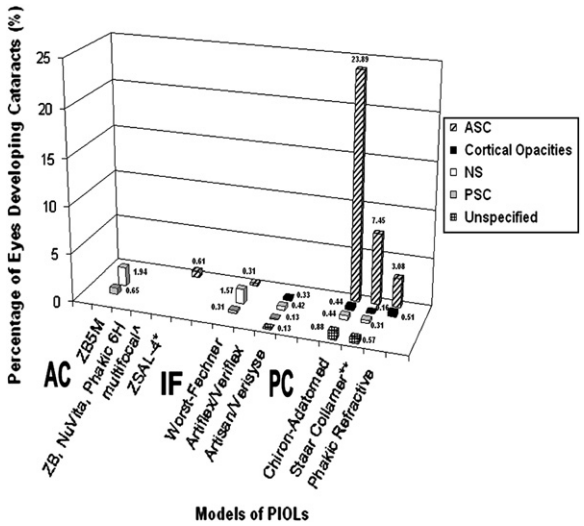

Figure 4. Types of new-onset and preexisting progressive cataracts with various pIOL models. Anterior subcapsular cataract was the predominant type in the PC pIOL group. Incidence of ASCs was much higher for those patients who received Chiron-Adatomed IOLs than Staar Collamer ICLs (AC = anterior chamber; ASC = anterior subcapsular cataract; IF = iris fixated; NS = nuclear sclerotic; PC = posterior chamber; PSC = posterior subcapsular cataract). ^Includes Newlife/Vivarte presbyopic pIOL and AMO multifocal pIOL prototype. *The ASCs with this lens model included 1 eye with both ASC and PSC. **The ASCs with this lens model included 4 eyes with both ASC and cortical opacities, 3 eyes with both ASC and NS, and 1 eye with both ASC and PSC.

and less predictability in cases with high refractive errors.[143] Clear lens extraction has the drawback of accommodation loss in young patients and an increased risk for RD.[6,109,144]

Phakic IOLs have the advantages of reversibility, high optical quality, potential gains in best corrected visual acuity because of retinal magnification in myopic eyes, amount of correction not limited by corneal thickness, and preservation of corneal architecture and accommodation.[145,146] They are implanted using standard microsurgical techniques, and the learning curve is not difficult for ophthalmic surgeons.[145,147] The combination of pIOL implantation and LASIK (bioptics) for extreme myopia correction and coexisting astigmatism correction seems promising.[65,79,116] Recent innovation in toric pIOLs make spherocylindrical correction available in a single surgery, especially in patients with thin corneas.[148,149] However, pIOLs are not without complications. Major concerns with the AC pIOLs include corneal endothelial loss, damage to the iridocorneal angle and glaucoma, pupil ovalization, and cataract formation. The complications of chronic low-grade iritis, late endothelial damage, and corneal decompensation after IF pIOL implantation remain a concern. Posterior chamber pIOLs are also called prelens IOLs.[112] Avoidance of pigment

dispersion and cataract formation is important in this group.[147] To decrease the incidence of the above complications, an ideal pIOL demands certain requirements, which are shown in Figure 5.[145,150,151]

Fitting of a proper pIOL requires correct power selection and length determination. The selection of optical power is based on the van der Heijde formula[152] for most nonfoldable AC pIOLs and IF pIOLs.[11,44,60,91] The formula contains the following parameters: preoperative and desired postoperative refraction in the spectacle plane, corneal power, and AC depth (ACD) (distance between the anterior corneal surface and the cardinal plane of the IOL). In this calculation, there is no need to measure axial length (AL); this is in contrast to the calculation in aphakic eyes.[152] The AL measurement can be misleading; a refractive surprise can occur as a result of a posterior staphyloma in myopia attenuation and reverberation of sound waves.[153] The predictability of refractive outcome was generally good in the AC and IF groups. The calculation of Staar Collamer PC pIOL power was performed with proprietary formulas with independent variables of preoperative SE refraction, vertex distance, keratometry, ACD, and corneal pachymetry.[112] The corneal thickness must be subtracted from the biometry value of the ACD to get the actual ACD.[7] Having early experience of undercorrections, Zaldivar et al.[115] and Davidorf et al.[114] suggest making adjustments to refine predictability based on target postoperative refraction, pIOL availability, and the surgeon's experience. It is not possible to obtain emmetropia in every patient because of the limitations in the power of the pIOL.[10] In our series, 16 eyes had reoperations for incorrect power calculation. In addition, 76 eyes had secondary refractive procedures for residual refractive error. One other patient had multiple surgeries in addition to treatment for incorrect power. Two patients with wrong calculation of the pIOL power had no surgical procedure.

- Easy insertion, removal, or exchange that does not require a large wound
- Adequate fixation not causing pressure over fixated tissue
- Relatively thin A–P diameter, not touching adjacent ocular tissue
- Good finish, polishing, and biocompatibility
- Large functional optic with no glare design
- Negative and positive spherocylindrical powers with multifocal correction
- Affordable

A–P = antero–posterior

Figure 5. Requirements of an ideal pIOL.[145,150,151]

The sizing of AC and PC pIOLs is very important. If the AC pIOL is too long, it vaults too much and may cause corneal endothelial damage, pupil ovalization, or angle erosion; conversely, if it is too short, it may cause IOL rotation, IOL displacement into the AC, and damage to the AC angle. If the PC pIOL is too long, it also vaults too much; this may lead to narrowing of the angle and iris pigment dispersion. It may also result in increased mechanical pressure on the ciliary body. If, however, the PC pIOL is too short, it may vault too little and contact the crystalline lens centrally. Decentration is also a possibility. It had been impossible to measure the internal corneal diameter or sulcus-to-sulcus distance precisely[25,59,154]; however, new anterior imaging techniques, including optical coherence tomography (OCT), have resulted in more reliable internal diameter measurements of the corneal diameter that can be used for sizing AC pIOLs and determining critical distances from the AC pIOL edge to the peripheral corneal endothelium and the shape of the iris (convex versus flat configuration).[154] At present, the limbal white-to-white (WTW) diameter is used to empirically estimate these distances. The AC pIOL length was approximated by measuring the horizontal WTW corneal diameter and adding 0.5 or 1.0 mm to it to fit the internal intertrabecular distance in myopia or hyperopia according to the pIOL model.[11,12,60,155] For the PC pIOL (except the PRL), 0.5 or 1.0 mm was added to the horizontal WTW diameter in myopia; 0.5 mm was subtracted in hyperopia.[110,112,114,115,156] However, after noticing a high incidence of cataracts, the manufacturing company now recommends implanting a hyperopic ICL 0.5 mm longer than the measured WTW.[157] For the PRL, the horizontal WTW distance is usually selected for myopic or hyperopic eyes.[47,139,142] However, Pop et al.[158] found using limbal measurement to estimate sulcus size is inadequate because limbus size alone cannot predict sulcus size. In contrast, the length of the IF pIOL was generally "one size fits all" (8.5 mm for adults, 7.5 mm for children or small eyes).[6,31,44,87,88]

The use of ultrasound biomicroscopy (UBM) can identify the distance between an AC pIOL or an IF pIOL and the corneal endothelium, iris, angle, and crystalline lens surface.[159–161] However, UBM cannot measure the internal corneal diameter.[59] For PC pIOLs, preoperative UBM can help detect the size of the ciliary sulcus and anomalies such as iridociliary cysts.[111,162] Postoperatively, it can locate the position of the PC pIOL in relation to the ciliary body, iris, lens, and zonules.[42,46,111,162] Recently, high-frequency

ultrasound biometry (50 MHz) and very high frequency ultrasound biometry (100 MHz) have been reported to be useful in delineating sulcus size.[25,47,163] Optical coherence tomography has been used to study the internal dimensions of the AC and pIOL vaulting; however, this imaging modality has limitations in exploring the PC behind the iris pigment as its energy is blocked by the iris pigment.[164]

Most patients who had pIOL surgery were older than 18 years and had stable myopia for 1 year. However, there were pediatric series[119,130] of PC pIOL implantation and case reports[165,166] of IF pIOL implantation (not included in our study) to treat anisometropic amblyopia with good results. There are safety guidelines for corneal endothelial count and ACD.[44] Most studies excluded ocular pathologies such as preexisting cataract and macular degeneration. Patients with peripheral retinal degeneration were accepted and treated with laser photocoagulation before pIOL surgery. Zaldivar et al.[116] suggest using LASIK to treat myopia up to −12.00 D, PC pIOL implantation to treat −12.00 to −18.00 D of myopia, and bioptics to treat myopia greater than −18.00 D.

Surgical maneuvers with various types of pIOLs should avoid trauma to the corneal endothelium, angle, and crystalline lens. Preoperatively, the pupil is constricted with the AC and IF pIOLs and widely dilated with the PC pIOL. The use of intraoperative miotics can reduce the risk for crystalline lens touch with AC and IF pIOLs. Phakic IOL implantation can be done under topical, sub-Tenon, peribulbar, retrobulbar, or general anesthesia according to surgeon preference and patient personality.[24,34,142] Three types of incisions can be performed in nonfoldable AC pIOL surgery: classic lateral corneal,[23] superior limbal,[60] and steepest meridian limbal.[4] A silicone slide sheet can be used to aid the introduction of the AC pIOL without damaging the crystalline lens.[4,60] Gonioscopic evaluation at the end of surgery to ensure good position of the haptic ends has been suggested.[4,167] With the IF pIOL, centration and fixation are the most crucial steps in terms of the immediate postoperative results. Care must be taken to make secure entrapment of the midperipheral iris fold to the iris claws with iris enclavation forceps or "iris crochet needles"[88] and make precise centration over the pupil.[9] If toric iris-claw IOLs are to be implanted, the desired location is marked preoperatively to obtain the correct axis of the IOL.[33,37] With the advent of the foldable Staar Collamer ICL, the properly oriented IOL can be implanted with an injector[115] or a forceps.[110] Separate maneuvers to gently tuck both footplates of the PC pIOL under the iris instead of rotationally dialing them in is suggested to avoid pigment dispersion and probable crystalline lens touch.[41,115,128] At the end of surgery, the pupil is constricted using an intraocular miotic agent. Although Baikoff and Colin[167] think that peripheral iridectomy is not always necessary when their IOLs are used, most surgeons recommend preoperative peripheral laser iridotomy or surgical iridectomy with all types of pIOLs to prevent pupillary block.[13,41,60,88] The surgical iridectomy site is chosen to avoid footplate incarceration of the AC pIOL.[167] Zaldivar et al.[115] suggest using an argon laser before applying Nd:YAG spots at least 4 days before PC pIOL implantation to decrease iris bleeding and pigment deposition on the pIOL. Hoffer[168] introduced an atraumatic pigment vacuum iridectomy technique with a 25-gauge cannula that might prevent the need for a preliminary laser iridectomy.

In our study, we found that the definition of *cataract* was arbitrary. Only 5 papers[27,43,51,53,128] from 3 studies used the Lens Opacities Classification System (LOCS) III[169] to assess lens opacities and 1 paper[141] used the LOCS II[170] to assess the clarity of the crystalline lens. In an attempt to classify the risk factors and mechanisms for cataract development, we divided them into the following categories.

Patient-Dependent Factors

Age at Phakic Intraocular Lens Implantation Based on their studies of pIOLs, Alió et al.,[53] Uusitalo et al.,[54] Menezo et al.,[74,75] Gonvers et al.,[129] Lackner et al.,[135] and Sarikkola et al.,[141] suggest that the older the patient at the time of IOL implantation, the higher the chance of cataract. Alió et al.[53] concluded that patients older than 40 years at the time of AC pIOL surgery have a higher incidence of nuclear cataract formation. Menezo et al.[74,75] also found that patient age (>40 years) can be considered a prognostic factor of nuclear cataract development after IF pIOL implantation. Gonvers et al.[129] propose that resistance to ICL-induced cataract decreases with age. In their series, 14% of young patients (aged 10 to 40 years) and 37% of older patients (aged 41 to 50 years) developed cataract. Uusitalo et al.[54] regard aging (44 years old at the time of ICL implantation) as one factor causing cataract formation in both eyes of a patient. In addition, the good results in the pediatric series[119,130] suggest that patients at a young age are more apt to tolerate a pIOL. A recently suggested age criterion (age <45 years) was proposed by the ICL manufacturer.[135] Baikoff et al.[101] report a recent insight into the effect of a convex iris shape that leads to increased lens rise with a higher postoperative risk for posterior synechias and subsequent cataract formation after Artisan/Artiflex pIOL implantation.

Refractive Status The prevalence of cataract is 4 times higher in patients with high myopia than in the normal

population.[171] Alió et al.,[53] Uusitalo et al.,[54] and Menezo et al.[75] suggest that an increase in AL could be a risk factor. Alió et al.[53] found that with AC pIOLs, eyes with an AL greater than 30.0 mm had a higher incidence of NS cataract. Similarly, Menezo et al.[75] suggest that AL (>30 mm) is a prognostic factor for nuclear cataract formation after IF pIOL implantation. Gonvers et al.[129] also showed that in eyes with PC pIOLs, myopia was more pronounced in the ASC group than in the clear lens group. In Sanders et al.'s study of ICLs,[43] all clinically significant cataracts (both NS and ASC) occurred in the group with myopia greater than −10.00 D.

Trauma Ocular trauma was more commonly associated with pIOL dislocation or subluxation than with cataract.[6,87,99,118] However, cataract might ensue from direct or indirect ocular trauma in the patient.[127,172] Alió et al.[53] and Sanders et al.[43] report 1 patient each with pIOL implantation developing cataract after vitreoretinal manipulation.

Clinical Inflammatory Reaction Iridocyclitis associated with pIOLs and topical steroid agents may induce cataract.[69] Postoperative acute uveitis and sterile hypopyon were easily controlled in most cases with steroid therapy within 1 or 2 weeks without sequela.[60,85,99,123] Nevertheless, Fechner et al.[55] report 2 eyes of a patient that rapidly developed cataracts, the formation of which originated from a violent reaction to PC pIOL insertion and collection of leukocytes between the natural and artificial lenses. Phakic IOL removal and cataract surgery were performed in both eyes within 1 week of pIOL surgery. Leccisotti and Fields[67] report 1 eye of a patient having 3 episodes of chronic iridocyclitis in the first 8 months after AC pIOL implantation. The eye developed cataract and posterior synechias that eventually required cataract surgery.

Preexisting Opacities Alió et al.[53] postulate that AC pIOL implantation in eyes with early changes in the nucleus might promote the progression of these changes into the development of a clinically significant NS cataract. Sarikkola et al.[141] found that preexisting lens opacity was a risk factor for cataract formation after ICL implantation. In our study, 19.67% of eyes with preexisting cataract ultimately required lens extraction surgery after pIOL surgery.

Intraocular Lens-Dependent Factors

Lens Model The anatomic location of the pIOL seems to play a role in cataract formation. Our analysis showed that the incidence of cataract was much higher with PC pIOLs than with AC and IF pIOLs. The PC pIOL, because of its proximity to the natural lens, has a higher chance of causing a pressure effect or metabolic imbalance of the lens.[153] The chronic subclinical inflammation induced by changes in the permeability of the BAB barrier after pIOL implantation also raises the concern of cataract formation, just as in uveitis and diabetes.[8,40,53,56,80] The continuous disruption of the BAB was related to contact between the uveal tissue (iris and ciliary body) and the pIOL.[7] Laser flare–cell meter measurement is an objective and reproducible method for in vivo evaluation of anterior segment inflammation.[95] Fluorophotometry provides another method for assessing the integrity of the BAB.[80] Fechner et al.,[91] using a laser flare–cell meter and iris fluorescence angiography, did not find anterior segment chronic inflammation for at least 13 months after Worst-Fechner biconcave IOL implantation. However, Alió et al.[72] detected much higher flare values in the Worst-Fechner group than in the Baikoff ZB5M group and thus regarded the Worst-Fechner biconcave IOL as a proinflammatory IOL. The unacceptable high flare values in the Alió et al. study might be due to an artifact during measurement with the laser flare–cell meter.[8,25,95] Pérez-Santonja et al.,[80] using fluorophotometry, showed an increase in the BAB that might last at least 14 months after Worst-Fechner biconcave IOL implantation. In a later study by Pérez-Santonja et al.,[8] postoperative flare values in the Worst-Fechner biconcave IOL group were higher than in the Baikoff ZB5M IOL group up to 24 months postoperatively, although the difference was not significant. The flare values of the Staar Collamer ICLs reported by Jiménez-Alfaro et al.[7] and Sanders[136] were much lower than those of the Worst-Fechner biconcave IOL and Baikoff ZB5M IOL reported by Pérez-Santonja et al.[8] Sanders[136] concluded implantation of the Staar Collamer IOL does not cause a long-term (2 to 3 years) inflammatory response in the eye.

Even when implanted in the same anatomic location, different IOL models result in a variable incidence of cataract. Because the Fyodorov and Chiron-Adatomed IOLs had a much higher incidence of cataract, they were discontinued. The incidence of cataract with the Chiron-Adatomed IOLs has been reported to be from 0%[123] to 52.9%.[109] Refinements in design of the Staar Collamer ICLs caused a significant drop in the incidence of cataract.[51,112] In the literature, the incidence of cataract with Staar Collamer ICLs is reported to be from 0%[7] to 33.3%.[134] In 12 patients, Menezo et al.[112] implanted a Chiron-Adatomed IOL in 1 eye and a Staar Collamer ICL in the other eye; there was a higher incidence of ASC in the former group (4/12 [33.3%] versus 3/12 [25.0%]). In our review, we found that the incidence of cataract formation was 25.66% with the Chiron-Adatomed pIOL and 8.48% with the Staar Collamer ICL and the percentage of cataract surgery

for new-onset cataract, 45.61% and 30.82%, respectively.

Higher cell deposit rates have been found with the Artiflex pIOL. Tahzib et al.[34] report a 54-year-old man who developed a severe cell deposition 1 week after implantation of a foldable Artiflex pIOL. Upon explantation of the pIOL, scanning electron microscopy showed multiple cell deposits. Kohnen et al.[173] evaluated the surface quality of new-generation pIOLs and found minor surface roughness only at the claws of an Artisan IF AC IOL.

Lens Vaulting Parameters of vaulting include the pIOL's overall length (overall diameter) and design (shape). In the AC and IF groups, a decrease in vault and thinner anteroposterior diameter helped lessen damage to the endothelium.[24,92] In the AC group, the pIOL–crystalline lens distance was estimated to be 0.78 to 1.96 mm with the ZB pIOL,[62] 0.48 to 0.81 mm with the ZB5M pIOL,[59] 0.79 ± 0.24 mm with the ZSAL-4 pIOL,[4] and 0.57 to 1.03 mm with the NuVita.[76] With IF pIOLs, the distance between the pIOL and the natural lens necessary to ensure adequate aqueous flow has been found to be 0.8 mm with the Worst-Fechner,[88] between 0.78 mm and 0.93 mm with the Artisan for myopia,[160] and between 0.35 mm and 0.79 mm with the Artisan for hyperopia.[159] The implantation of a pIOL in the AC is thought to induce less cataract formation than implantation in the PC because the distance between the pIOL and the natural lens is larger in the former, minimizing the risk for progressive mutual contact between the pIOL and the natural lens.[174,175]

In the PC group, IOL size plays an important role in the extent of vault.[111] Phakic IOLs with increased diameter, and thus increased vault, buckle forward. Although the incidence of cataracts was less, there was increase in pigment dispersion and angle closure glaucoma.[22,156] Phakic IOLs with decreased diameter and less vault, by virtue of their close proximity to the crystalline lens, could increase the incidence of cataract[22] and lead to decentration, halos, and glare. A central vault of 0.15 mm has been described as ideal to protect the lens from the IOL contact.[129] Insufficient vault might provoke cataract formation by mechanical irritation or traumatism of the anterior capsule.[46] Poor vault could also lead to disturbances in aqueous flow, interference with lens metabolism for preventing oxidative damage,[176] and cataract formation.[153] In addition, IOL rotation and change in vault were found during accommodation and pupil light response.[127,163,177] This anteroposterior movement and rotation of the IOL might cause repeated microtrauma to the natural lens and hence cataract development.[7,46,141] Furthermore, the extent of vault could also be reduced over time due to increasing thickness of the crystalline lens or erosion of the PC pIOL into the sulcus.[76,129,164] Most authors attribute late-onset cataract to IOL–crystalline contact and/or repeated microtrauma resulting from IOL movement.[7,51,55] In our analysis, in reports in which data were available, 36 eyes (80%) were documented to have poor vault among the 45 late-onset ASCs (≥1 year). It was suspected that central and/or peripheral contact between the IOL and the crystalline lens was responsible for the high rate of ASC in the PC pIOL group.[129,140] The evidence of ring opacity corresponding to the area of "touch" of the lens capsule to the optic edge of the Chiron-Adatomed IOL supported this hypothesis.[150] Further evidence was revealed by Sarikkola et al.[141] that the appearance of ASC was first seen beneath the thickest part of the ICL as a circle on the anterior surface of the natural lens in myopic eyes and in the central area in hyperopic eyes.

Vaulting may be affected by the design of a pIOL. An increase in vault of the Staar Collamer pIOL compared with the Chiron-Adatomed IOL significantly decreased cataractogenesis.[112] Zaldivar et al.[178] report that Staar Collamer ICLs with the V3 and V4 models had less vaulting than the V1 and V2 models and hence a higher incidence of cataract formation. They found that the first-generation pIOLs (up to model V2), which largely vaulted over the crystalline lens, led to no ICL-induced cataracts in a series of 124 eyes.[115] In contrast, with the third and fourth generations, which had a better design but less vault, an 8.5% rate of cataract was reported during 3-year follow-up.[178]

By decreasing the posterior radius of the ICL's curvature, the model V4 ICL was more curved than the model V3 and presumed to offer better vaulting.[122] In a short-term study by Gonvers et al.,[122] the model V4 offered better vaulting over the crystalline lens than the model V3, which should decrease the risk for cataract. Sanders and Vukich[51] also found significant pronounced vaulting with the model V4 compared with the model V3. The presence of poor vault in the V3 group compared with that in the V4 group (23.6% versus 4.3%) was highly correlated with the development of late-onset ASCs (9.2% versus 0.6%).[51] This was also observed by Sarikkola et al.[141] The model V3 ICL is not currently in use due to poor vault and potential cataractogenesis.[112] However, in another study, Gonvers et al.[129] found no statistically significant difference in vaulting between models V3 and V4. Considering this, there appears to be no definite consensus in the literature that modifying the design from V3 to V4 has resulted in better vaulting.[129]

The ability to measure the sulcus-to-sulcus distance may provide better biometric parameters for surgical

planning for adequate vaulting of the PC pIOL than the currently employed WTW measurement.[122,163] Excessive vaulting also may induce contact between the haptics of the ICL and the periphery of the crystalline lens.[127,138,179]

Lens Material All recent nonfoldable IOLs in the AC pIOL and IF pIOL groups were made of poly(methyl methacrylate) (PMMA). High-molecular-weight PMMA is biologically almost inert and can be tolerated by the eye over the long term,[173] although low-molecular-weight PMMA has led to a tragic history of long-term snowflake degeneration.[180] The ZB5MF pIOL, a modification of ZB5M model, contains a fluorine surface treatment to improve biocompatibility of the lens.[53,60] In the PC pIOL group, the earlier silicone IOLs (Fyodorov and Chiron-Adatomed) were relatively hydrophobic, bioincompatible,[150] and associated with a higher incidence of cataract.[156] Staar Collamer ICLs contain collagen, are hydrophilic and biocompatible,[112] and are therefore believed to cause fewer cataracts.[40] Trindade et al.[111,126] observed no lens opacification for more than 2 years in eyes with ICL implantation despite IOL–crystalline contact at the optic–haptic junction in the midperiphery. They credit this to the proper biocompatibility of the ICL hydrophilic material. Even though PRLs are made of silicone, they have a higher refractive index and are ultrathin.[41] The hydrophobic nature of the material is postulated to allow the IOL to "float" on the natural lens.[40]

Surgeon-Dependent Factors

Surgical Trauma Surgical trauma was one of the most important risk factors in the PC pIOL group in early cataract cases.[52,128] Inadvertent lens touch during PC pIOL insertion usually resulted in nonprogressive ASCs or anterior cortical cataracts,[45,55,120] whereas more vigorous repositioning of an inverted IOL within the eye might induce visually significant ASC.[115] In a series by Sanders and Vukich,[51] removal and reinsertion during surgery or on the same day of surgery as a result of the ICL being implanted upside down was associated with increased cataract. Sánchez-Galeana et al.[52] and Sanders and Vukich[51] observed that most of the early-onset ($\leq$3 months) ASCs were frequently asymptomatic and highly associated with surgical trauma. In our analysis, of the 17 eyes with cataract developing within 1 week of PC pIOL implantation, 14 had a history of intraoperative trauma and 2 had severe postoperative inflammation.[45,48,50,51,55,110,128] The crystalline lens may also be damaged during surgical iridectomy[48,168] or by preoperative Nd:YAG laser treatment,[115,137,181] causing cataract.[54]

Surgeon Learning Curve Sanders and Vukich[51] found that the incidence of lens opacities increased with inexperienced surgeons (within the first 7 implantations of each surgeon) compared with later eyes. Two of 19 surgeons were responsible for the majority of observed lens opacities. Sánchez-Galeana et al.[52] report that 79% opacities in the first or second implantation of inexperienced surgeons. Sánchez-Galeana et al. also report that with increased surgical experience, the incidence of opacities dropped from 19% to 0% with the same surgeon.[52]

Other Factors

Length of Follow-up The incidence of cataracts was higher in patients followed for a longer period.[109,112] Sanders et al.,[43] Menezo et al.,[74,75,96] Trindade and Pereira,[126] Fink et al.,[127] Gonvers et al.,[129] and Sarikkola et al.[141] found that cataracts that were not seen in previous shorter-term clinical series[54,89,111,113,122,128] occurred after a longer follow-up. Cataracts developing over a longer follow-up were attributed to the impact of the IOL on the crystalline lens[109,112,127] and/or the natural morbidity of senile cataract.[74,75,87,96,129]

Type of Cataract The rate of progression varied for different types of cataracts. In our study, we found that the most common type of new-onset cataract in the AC and IF groups was NS and in the PC group was ASC. New-onset NS cataracts in the AC and IF groups were observed years after implantation and were not ascribed to pIOL surgery.[60,75,87,94,96] All new-onset NS cataracts in the AC and IF groups required surgery. Most new-onset ASCs in the PC group were nonprogressive (focal ASCs) or slowly progressive, and 31.19% required surgery. Slowly progressive ASCs, which might impair vision, could present as ring configurations concentric to the optical zone; as central gray–white opacities; or as a diffuse, dense pattern.[52,75,112] Cataracts would progress faster once NS developed after diffuse ASC.[52] All new-onset NS cataracts in the PC group were visually significant. All new-onset cortical cataracts in each group were nonprogressive and asymptomatic. They appeared as discrete anterior cortical opacities and/or vacuoles and were strongly associated with surgical trauma.[3,45,78] Few new-onset cataracts were PSC, although PSC is a specific type of cataract in high myopia or in the normal aging population.[171,182,183]

Thus far, we have discussed the correlation between surgical trauma during pIOL implantation and the formation of ASCs or anterior cortical cataracts. Which type of cataract is more likely to develop after anterior segment procedures, even without lenticular touch? For instance, after trabeculectomy, cataract formation is considered to be more likely in cases of AC

shallowing, air in the AC, IOP rise, hypotony, hyphema, uveitis, and possibly irregular circulation of aqueous through the fistula.[127] However, these cataracts tend to be NS or PSC. High myopia alone can predispose to cataract formation, but usually of the PSC or NS variety.[127,171] Anterior subcapsular cataract is not a typical form of senile cataract.[126] In our study, 90.58% of all new-onset cataracts after PC pIOL implantation were ASCs. If unspecified type were excluded, 96.19% of all new-onset cataracts after PC pIOL implantation were ASCs. This might imply that ASC formation is related to PC pIOL, per se. Early-onset ASCs ($\leq$3 months after surgery) were closely related to surgical trauma,[51,52,128] whereas late-onset ($\geq$1 year after surgery) ASCs were related to poor vault.[51] Anterior subcapsular cataract was considered to be typical of a PC pIOL–induced cataract.[75,129]

Steroid Use Steroids were more commonly associated with increased IOP than with cataracts.[23,79,92,108,115] However, one cannot ignore the fact that an excessive postoperative steroid regimen was a potential cause of cataract formation.[44]

Pilocarpine Use Cataract development due to PC flattening could occur immediately after the administration of cholinergic agonists such as pilocarpine in an eye with a hyperopic ICL.[175]

Ophthalmic Viscosurgical Devices Surgical procedures for different types of pIOL explantation and cataract surgery should use high-viscosity OVDs liberally to protect corneal endothelium. The explantation wound should be made slightly wider than the total diameter of the nonfoldable pIOL to ensure its extraction from the eye without difficulty. Usually, 2 side-port incisions at the opposite directions perpendicular to the scleral wound were made to facilitate further intraocular manipulation in the AC and IF groups.[53,96] The importance of excluding the existence of unrevealed synechias in the AC angle before rotating the superior haptic out from the angle when removing an AC pIOL could not be overemphasized.[53] Once the haptic was extracted into the scleral tunnel, the AC pIOL could easily be explanted with a forceps. Then, the scleral wound was partially closed for phacoemulsification.[53] The technique of explanting an IF pIOL was relatively simple.[87] The iris was liberated from the slits of the haptic, and the freed IOL was oriented parallel to the scleral wound and extracted from the AC with ease.[87,96] Again, the scleral tunnel was partially sutured for phacoemulsification. When explanting earlier models of silicone PC pIOL, the key point was to check and lyse any possible adherence between the pIOL and the anterior capsule of the crystalline lens before the pIOL was simply extracted.[75,153] Explantation of an ICL was easy to perform through the original, unenlarged, primary clear corneal incision because of its remarkable elasticity.[126,131,138,156] The haptics of the ICL were dislocated from behind the iris with a hook and the optic was fixed with a forceps and was explanted smoothly.[52,140,157] Cataract surgery with phacoemulsification and PC IOL implantation could be performed in a routine fashion in all pIOL groups.[52,53,87,96,126,156] Alió et al.[53] believed it was safer to perform phacoemulsification in the AC in high myopic eyes because of the long scleral tunnel and the soft nature of the cataracts. The biometry and IOL power calculation for cataract operation did not seem to be distorted by the presence of a pIOL except for silicone PC pIOLs.[52,53,96,126,153] The amount of error in ultrasound measurement depends on the power of the pIOL and its material. Hoffer[184] provided a mathematical correction of ultrasound AL measurement in the presence of a pIOL. The correction value is highest with a silicone plate pIOL in an eye with very high hyperopia and lowest with an ICL in an eye with very high myopia. In all reported cases, cataract surgery followed by PC IOL implantation was successful. The final visual acuity could be restored to the level before cataract development.

It is dangerous to jump to the conclusion that IF pIOLs are "better" than PC pIOLs solely because the incidence of cataract was lowest with the IF pIOLs. Use of pIOLs implanted in the ACs was limited by chronic corneal endothelial loss, which might ensue from intermittent touch between the IOL optic edge and the corneal midperiphery during eye rubbing.[34,58,62,73,95,173] With the modification of new generations of pIOLs with lower and thinner profiles and the instruction to patients not to rub their eyes, the possibility of IOL–cornea touch could be minimized.[9,11] Another reason for progressive corneal endothelial loss, particularly with IF pIOLs, was chronic subclinical inflammation.[8,73,95] The reports of corneal decompensation and transplantation in the IF group raises the alarm of regular continuous monitoring of the health of the corneal endothelium.[9,10,87] It is mandatory to explant the pIOL before a critical breakdown is recognized by corneal edema. To ensure long-term safety, eyes to have implantation of an IF pIOL must have sufficient ACD (at least from 3.0 to 3.6 mm, depending on the age of the patient and the IOL power) to provide a safe clearance between the IOL and the endothelium.[9,87,91–93] Patients who have IF pIOL implantation must understand and accept the need for scheduled examinations of the corneal endothelium every 6 to 12 months throughout their lives.[87,91] They should visit ophthalmic practices and clinics where authoritative noncontact specular

microscopy and photography of the endothelium are available as a record for future comparison.[87,92,93] The local ophthalmologist must also understand the necessity of endothelial microscopy and if required, be able to refer the patient to a corneal specialist. Under all these circumstances, IF pIOLs may be better than PC pIOLs. Ten-year follow-up results reported by Tahzib et al.[185] show that implantation of an Artisan pIOL for the correction of moderate to high myopia is a stable, predictable, and safe method when strict inclusion criteria for surgery are applied. There was no significant loss of corneal endothelial cells and no reports of long-term glare. Newer imaging techniques such as OCT are important to exclude patients at risk for synechia formation and endothelial cell loss.[164] However, whether patients will comply with the life-long, stringent stipulation of constant checkups is highly questionable.[93]

CONCLUSION

Phakic IOL implantation as performed today seems to be a safe and promising alternative to keratorefractive procedures. The incidence of cataract formation was relatively higher in eyes with PC pIOLs, which might be due to the close proximity of the IOL to the natural lens. Anterior subcapsular cataract was a predominant and typical type of cataract in the PC pIOL group. Punctate ASC, usually nonprogressive, was probably related to surgical trauma. Diffuse pattern, ring-pattern, and central dense pattern ASCs in the PC group were slowly progressive and might be associated with insufficient vault. Nuclear sclerotic cataracts in the AC and IF groups were unrelated to pIOL surgery, and all patients with new-onset NS in theses 2 groups required cataract surgery. Once NS was detected after pIOL surgery, no matter which anatomic location the pIOL was implanted in, there was a very high likelihood of significant visual impairment. Therefore, patients having pIOL implantation should be regularly examined for any NS development. Although most papers in our study excluded preexisting cataracts, we still found that approximately 20% of preexisting cataracts required definitive cataract surgery. Although the technique to explant pIOLs is not difficult, one should estimate the risks of pIOL implantation and explantation surgery in addition to cataract surgery in eyes with high myopia. It is probably better to warn patients who have preexisting opacities about the possibility of cataract progression and reoperation and to reconsider refractive lensectomy plus PC IOL implantation instead. Most patients had excellent visual restoration after cataract surgery. In addition to cataract, pIOL removal must be considered in eyes with AC pIOLs that develop halos and/or glare in the AC group and in eyes with IF pIOLs that have endothelial loss. Intraocular pressure increase was the second most common reason for removal of PC pIOLs.

The short learning curve, reversibility, lens exchangeability, and excellent visual rehabilitation make pIOL surgery appealing. Although the initial results are promising, repeat surgery for cataract may be unacceptable to young patients with low to intermediate myopia whose level of expectation is high. Apart from cataracts, which can be handled surgically, other vision-threatening complications may lead to disastrous consequences. Risks of an invasive intraocular procedure must also be kept in mind.

Careful patient selection is an essential prerequisite to pIOL implantation. Life-long, yearly follow-up may be necessary to ensure that pIOLs are safe for the patient. Patients having PC pIOL implantation should be informed of the potential risk for cataract development and corneal endothelial decompensation.

REFERENCES

1. Sanders DR, Brown DC, Martin RG, Shepherd J, Deitz MR, DeLuca M. Implantable contact lens for moderate to high myopia; phase 1 FDA clinical study with 6 month follow-up. J Cataract Refract Surg 1998; 24:607–611
2. Sanders DR, Martin RG, Brown DC, Shepherd J, Dietz MR, DeLuca M. Posterior chamber phakic intraocular lens for hyperopia. J Refract Surg 1999; 15:309–315
3. Maloney RK, Nguyen LH, John ME. Artisan phakic intraocular lens for myopia; short-term results of a prospective, multicenter study; the Artisan Lens Study Group. Ophthalmology 2002; 109:1631–1641
4. Pérez-Santonja JJ, Alió JL, Jiménez-Alfaro I, Zato MA. Surgical correction of severe myopia with an angle-supported phakic intraocular lens. J Cataract Refract Surg 2000; 26:1288–1302
5. Garrana RMR, Azar DT. Phakic intraocular lenses for correction of high myopia. Int Ophthalmol Clin 1999; 39(1):45–57
6. Budo C, Hessloehl JC, Izak M, Luyten GPM, Menezo JL, Sener BA, Tassignon MJ, Termote H, Worst JGF. Multicenter study of the Artisan phakic intraocular lens. J Cataract Refract Surg 2000; 26:1163–1171
7. Jiménez-Alfaro I, Benitez del Castillo JM, García-Feijoó J, Gil de Bernabé JG, Serrano de la Iglesia JM. Safety of posterior chamber phakic intraocular lenses for the correction of high myopia; anterior segment changes after posterior chamber phakic intraocular lens implantation. Ophthalmology 2001; 108:90–99; discussion by SM MacRae, 99
8. Pérez-Santonja JJ, Iradier MT, Benítez del Castillo JM, Serrano JM, Zato MA. Chronic subclinical inflammation in phakic eyes with intraocular lenses to correct myopia. J Cataract Refract Surg 1996; 22:183–187
9. Fechner PU, Haubitz I, Wichmann W, Wulff K. Worst-Fechner biconcave minus power phakic iris-claw lens. J Refract Surg 1999; 15:93–105
10. Landesz M, Worst JGF, Siertsema JV, van Rij G. Negative implant; a retrospective study. Doc Ophthalmologica 1993; 83:261–270

11. Baikoff G, Arne JL, Bokobza Y, Colin J, George JL, Lagoutte F, Lesure P, Montard M, Saragoussi JJ, Secheyron P. Angle-fixated anterior chamber phakic intraocular lens for myopia of −7 to −19 diopters. J Refract Surg 1998; 14:282–293
12. Allemann N, Chamon W, Tanaka HM, Mori ES, Campos M, Schor P, Bäikoff G. Myopic angle-supported intraocular lenses; two-year follow-up. Ophthalmology 2000; 107:1549–1554
13. Ardjomand N, Kölli H, Vidic B, Vidic B, El-Shabrawi Y, Faulborn J. Pupillary block after phakic anterior chamber intraocular lens implantation. J Cataract Refract Surg 2002; 28:1080–1081
14. Bylsma SS, Zalta AH, Foley E, Osher RH. Phakic posterior chamber intraocular lens pupillary block. J Cataract Refract Surg 2002; 28:2222–2228
15. Ruiz-Moreno JM, Alió JL, Pérez-Santonja JJ, de la Hoz F. Retinal detachment in phakic eyes with anterior chamber intraocular lenses to correct severe myopia. Am J Ophthalmol 1999; 127:270–275
16. Rizzo S, Belting C, Genovesi-Ebert F. Two cases of giant retinal tear after implantation of a phakic intraocular lens. Retina 2003; 23:411–413
17. Pérez-Santonja JJ, Ruiz-Moreno JM, de la Hoz F, Giner-Gorriti C, Alió JL. Endophthalmitis after phakic intraocular lens implantation to correct high myopia. J Cataract Refract Surg 1999; 25:1295–1298
18. Strampelli B. Sopportabilita' di lenti acriliche in camera anteriore nella afachia e nei vizi di refrazione. [Tolerance of acrylic lenses in the anterior chamaber in aphakia and refraction disorders.]. Ann Ottalmol Clin Ocul 1954; 80:75–82
19. Drews RC. The Barraquer experience with intraocular lenses; 20 years later. Ophthalmology 1982; 89:386–393
20. Neuhann T. Corneal or lens refractive surgery? [editorial] J Refract Surg 1998; 14:272–273
21. Werner L, Apple DJ, Izak AM, Pandey SK, Trivedi RH, Macky TA. Phakic anterior chamber intraocular lenses. Int Ophthalmol Clin 2001; 41(3):133–152
22. O'Brien TP, Awwad ST. Phakic intraocular lenses and refractory lensectomy for myopia. Curr Opin Ophthalmol 2002; 13:264–270
23. Baikoff G, Joly P. Comparison of minus power anterior chamber intraocular lenses and myopic epikeratoplasty in phakic eyes. Refract Corneal Surg 1990; 6:252–260
24. Baikoff G. Intraocular phakic implants in the anterior chamber. Int Ophthalmol Clin 2000; 40(3):223–235
25. Alió JL. Advances in phakic intraocular lenses: indications, efficacy, safety, and new designs. Curr Opin Ophthalmol 2004; 15:350–357
26. Baïkoff G, Matach G, Fontaine A, Ferraz C, Spera C. Correction of presbyopia with refractive multifocal phakic intraocular lenses. J Cataract Refract Surg 2004; 30:1454–1460
27. Alió JL, Mulet ME. Presbyopia correction with an anterior chamber phakic multifocal intraocular lens. Ophthalmology 2005; 112:1368–1374
28. Fechner PU, Worst JGF. A new concave intraocular lens for the correction of myopia. Eur J Implant Refract Surg 1989; 1:41–43
29. Fechner PU. Die Irisklauen-Linse [Iris claw lens.]. Klin Monatsbl Augenheilkd 1987; 191:26–29
30. Landesz M, Worst JGF, Siertsema JV, van Rij G. Correction of high myopia with the Worst myopia claw intraocular lens. J Refract Surg 1995; 11:16–25
31. Dick HB, Alió J, Bianchetti M, Budo C, Christiaans BJ, El-Danasoury MA, Güell JL, Krumeich J, Landesz M, Loureiro F, Luyten GPM, Marinho A, Rahhal MS, Schwenn O, Spirig R, Thomann U, Venter J. Toric phakic intraocular lens: European multicenter study. Ophthalmology 2003; 110:150–162
32. U.S. Food and Drug Administration, Center for Devices and Radiological Health ARTISAN®(Model 206 and 204) phakic intraocular lens (PIOL) Verisyse™ (VRSM5US and VRSM6US) phakic intraocular lens (PIOL) – PO300282004; updated. Rockville, MD, Center for Devices and Radiological Health, January 21, 2005. Available at: http://www.fda.gov/cdrh/pdf3/p030028.html. Accessed April 13, 2008
33. Güell JL, Vázquez M, Malecaze F, Manero F, Gris O, Velasco F, Hulin H, Pujol J. Artisan toric phakic intraocular lens for the correction of high astigmatism. Am J Ophthalmol 2003; 136:442–447
34. Tahzib NG, Eggink FAGJ, Frederik PM, Nuijts RMMA. Recurrent intraocular inflammation after implantation of the Artiflex phakic intraocular lens for the correction of high myopia. J Cataract Refract Surg 2006; 32:1388–1391
35. Alió JL, Mulet ME, Gutiérrez R, Galal A. Artisan toric phakic intraocular lens for correction of astigmatism. J Refract Surg 2005; 21:324–331
36. Bartels MC, Santana NTY, Budo C, van Rij G, Mulder PGH, Luyten GPM. Toric phakic intraocular lens for the correction of hyperopia and astigmatism. J Cataract Refract Surg 2006; 32:243–249
37. Bartels MC, Saxena R, van den Berg TJPT, van Rij G, Mulder PGH, Luyten GPM. The influence of incision-induced astigmatism and axial lens position on the correction of myopic astigmatism with the Artisan toric phakic intraocular lens. Ophthalmology 2006; 113:1110–1117
38. Tehrani M, Dick HB. Short-term follow-up after implantation of a foldable iris-fixated intraocular lens in phakic eyes. Ophthalmology 2005; 112:2189–2195
39. Coullet J, Guëll J-L, Fournié P, Grandjean H, Gaytan J, Arné J-L, Malecaze F. Iris-supported phakic lenses (rigid vs foldable version) for treating moderately high myopia: randomized paired eye comparison. Am J Ophthalmol 2006; 142: 909–916
40. Werner L, Apple DJ, Pandey SK, Trivedi RH, Izak AM, Macky TA. Phakic posterior chamber intraocular lenses. Int Ophthalmol Clin 2001; 41(3):153–174
41. Zaldivar R, Ricur G, Oscherow S. The phakic intraocular lens implant: in-depth focus on posterior chamber phakic IOLs. Curr Opin Ophthalmol 2000; 11:22–34
42. Assetto V, Benedetti S, Pesando P. Collamer intraocular contact lens to correct high myopia. J Cataract Refract Surg 1996; 22:551–556
43. Sanders DR, Doney K, Poco MICL in Treatment of Myopia (ITM) Study Group. United States Food and Drug Administration clinical trial of the Implantable Collamer Lens (ICL) for moderate to high myopia; three-year follow-up for the. Ophthalmology 2004; 111:1683–1692
44. Lovisolo CF, Reinstein DZ. Phakic intraocular lenses. Surv Ophthalmol 2005; 50:549–587
45. Hoyos JE, Dementiev DD, Cigales M, Hoyos-Chacón J, Hoffer KJ. Phakic refractive lens experience in Spain. J Cataract Refract Surg 2002; 28:1939–1946
46. García-Feijoó J, Jiménez Alfaro I, Cuiña-Sardiña R, Méndez-Hernandez C, Benítez del Castillo JM, García-Sánchez J. Ultrasound biomicroscopy examination of posterior chamber phakic intraocular lens position. Ophthalmology 2003; 110:163–172
47. García-Feijoó J, Hernández-Matamoros JL, Castillo-Gómez A, Lázaro C, Méndez-Hernández C, Martín T, Martínez de la Casa JM, García-Sánchez J. High-frequency ultrasound biomicroscopy of silicone posterior chamber phakic intraocular lens for hyperopia. J Cataract Refract Surg 2003; 29: 1940–1946

48. Pallikaris IG, Kalyvianaki MI, Kymionis GD, Panagopoulou SI. Phakic refractive lens implantation in high myopic patients: one-year results. J Cataract Refract Surg 2004; 30:1190–1197
49. Hoyos JE, Cigales M, Hoyos-Chacón J. Zonular dehiscence two years after phakic refractive lens (PRL) implantation. J Refract Surg 2005; 21:13–17
50. Donoso R, Castillo P. Correction of high myopia with the PRL phakic intraocular lens. J Cataract Refract Surg 2006; 32:1296–1300
51. Sanders DR, Vukich JA. Incidence of lens opacities and clinically significant cataracts with the Implantable Contact Lens: comparison of two lens designs; the ICL in Treatment of Myopia (ITM) Study Group. J Refract Surg 2002; 18:673–682
52. Sánchez-Galeana CA, Smith RJ, Sanders DR, Rodríguez FX, Litwak S, Montes M, Chayet AS. Lens opacities after posterior chamber phakic intraocular lens implantation. Ophthalmology 2003; 110:781–785
53. Alió JL, de la Hoz F, Ruiz-Moreno JM, Salem TF. Cataract surgery in highly myopic eyes corrected by phakic anterior chamber angle-supported lenses. J Cataract Refract Surg 2000; 26:1303–1311
54. Uusitalo RJ, Aine E, Sen NH, Laatikainen L. Implantable contact lens for high myopia. J Cataract Refract Surg 2002; 28:29–36
55. Fechner PU, Haigis W, Wichmann W. Posterior chamber myopia lenses in phakic eyes. J Cataract Refract Surg 1996; 22:178–182
56. Benitez del Castillo JM, Hernandez JL, Iradier MT, del Rio MT, García Sanchez J. Fluorophotometry in phakic eyes with anterior chamber intraocular lens implantation to correct myopia. J Cataract Refract Surg 1993; 19:607–609
57. Colin J, Mimouni F, Robinet A, Conrad H, Mader P. The surgical treatment of high myopia: comparison of epikeratoplasty, keratomileusis and minus power anterior chamber lenses. Refract Corneal Surg 1990; 6:245–251
58. Saragoussi JJ, Cotinat J, Renard G, Savoldelli M, Abenhaim A, Pouliquen Y. Damage to the corneal endothelium by minus power anterior chamber intraocular lenses. Refract Corneal Surg 1991; 7:282–285
59. Saragoussi J-J, Puech M, Assouline M, Berges O, Pouliquen YJ. Ultrasound biomicroscopy of Baikoff anterior chamber phakic intraocular lenses. J Refract Surg 1997; 13:135–141; correction, 329
60. Alió JL, de la Hoz F, Pérez-Santonja JJ, Ruiz-Moreno JM, Quesada JA. Phakic anterior chamber lenses for the correction of myopia: a 7-year cumulative analysis of complications in 263 cases. Ophthalmology 1999; 106:458–466
61. Jiménez-Alfaro I, García-Feijoó J, Pérez-Santonja JJ, Cuiña R. Ultrasound biomicroscopy of ZSAL-4 anterior chamber phakic intraocular lens for high myopia. J Cataract Refract Surg 2001; 27:1567–1573
62. Mimouni F, Colin J, Koffi V, Bonnet P. Damage to the corneal endothelium from anterior chamber intraocular lenses in phakic myopic eyes. Refract Corneal Surg 1991; 7:277–281
63. Alió JL, Ruiz-Moreno JM, Artola A. Retinal detachment as a potential hazard in surgical correction of severe myopia with phakic anterior chamber lenses. Am J Ophthalmol 1993; 115:145–148; correction, 831
64. Leccisotti A, Fields SV. Angle-supported phakic intraocular lenses in eyes with keratoconus and myopia. J Cataract Refract Surg 2003; 29:1530–1536
65. Muñoz G, Alió JL, Montés-Micó R, Belda JI. Angle-supported phakic intraocular lenses followed by laser-assisted in situ keratomileusis for the correction of high myopia. Am J Ophthalmol 2003; 136:490–499
66. Ferreira de Souza R, Forseto A, Nosé R, Belfort R Jr, Nosé W. Anterior chamber intraocular lens for high myopia; five year results. J Cataract Refract Surg 2001; 27:1248–1253
67. Leccisotti A, Fields SV. Clinical results of ZSAL-4 angle-supported phakic intraocular lenses in 190 myopic eyes. J Cataract Refract Surg 2005; 31:318–323
68. Leccisotti A. Angle-supported phakic intraocular lenses in hyperopia. J Cataract Refract Surg 2005; 31:1598–1602
69. Leccisotti A. Iridocyclitis associated with angle-supported phakic intraocular lenses. J Cataract Refract Surg 2006; 32:1007–1010
70. Leccisotti A. Bioptics by angle-supported phakic lenses and photorefractive keratectomy. Eur J Ophthalmol 2005; 15:1–7
71. Kwon SW, Moon HS, Shyn KH. Visual improvement in high myopic amblyopic adult eyes following phakic anterior chamber intraocular lens implantation. Korean J Ophthalmol 2006; 20:87–92. Available at: http://pdf.medrang.co.kr/paper/pdf/Kjo/Kjo020-02-03.pdf. Accessed April 13, 2008
72. Alió JL, de la Hoz F, Ismail MM. Subclinical inflammatory reaction induced by phakic anterior chamber lenses for correction of high myopia. Ocul Immunol Inflamm 1993; 1:219–223
73. Pérez-Santonja JJ, Iradier MT, Sanz-Iglesias L, Serrano JM, Zato MA. Endothelial changes in phakic eyes with anterior chamber intraocular lenses to correct high myopia. J Cataract Refract Surg 1996; 22:1017–1022
74. Menezo JL, Peris-Martínez C, Cisneros AL, Martínez-Costa R. Phakic intraocular lenses to correct high myopia: Adatomed, Staar, and Artisan. J Cataract Refract Surg 2004; 30:33–44
75. Menezo JL, Peris-Martínez C, Cisneros-Lanuza AL, Martínez-Costa R. Rate of cataract formation in 343 highly myopic eyes after implantation of three types of phakic intraocular lenses. J Refract Surg 2004; 20:317–324
76. Baumeister M, Bühren J, Kohnen T. Position of angle-supported, iris-fixated, and ciliary sulcus-implanted myopic phakic intraocular lenses evaluated by Scheimpflug photography. Am J Ophthalmol 2004; 138:723–731
77. Aguilar-Valenzuela L, Lleó-Pérez A, Alonso-Muñoz L, Casanova-Izquierdo J, Pérez-Moltó FJ, Rahhad MS. Intraocular pressure in myopic patients after Worst-Fechner anterior chamber phakic intraocular lens implantation. J Refract Surg 2003; 19:131–136
78. Alexander L, John M, Cobb L, Noblitt R, Barowsky RTUS. clinical investigation of the Artisan myopia lens for the correction of high myopia in phakic eyes. Report of the results of phases 1 and 2, and interim phase 3. Optometry 2000; 71:630–642
79. Güell JL, Vazquez M, Gris O, De Muller A, Manero F. Combined surgery to correct high myopia: iris claw phakic intraocular lens and laser in situ keratomileusis. J Refract Surg 1999; 15:529–537
80. Pérez-Santonja JJ, Hernández JL, Benítez del Castillo JM, Rodríguez-Bermejo C, Zato MA. Fluorophotometry in myopic phakic eyes with anterior chamber intraocular lenses to correct severe myopia. Am J Ophthalmol 1994; 118:316–321
81. El Danasoury MA, El Maghraby A, Gamali TO. Comparison of iris-fixed Artisan lens implantation with excimer laser in situ keratomileusis in correcting myopia between −9.00 and −19.50 diopters; a randomized study. Ophthalmology 2002; 109:955–964
82. Landesz M, van Rij G, Luyten G. Iris-claw phakic intraocular lens for high myopia. J Refract Surg 2001; 17:634–640
83. Krumeich JH, Daniel J, Gast R. Closed-system technique for implantation of iris-supported negative-power intraocular lens. J Refract Surg 1996; 12:334–340

84. Güell JL, Vázquez M, Gris O. Adjustable refractive surgery: 6-mm Artisan lens plus laser in situ keratomileusis for the correction of high myopia. Ophthalmology 2001; 108:945–952
85. Alió JL, Mulet ME, Shalaby AMM. Artisan phakic iris claw intraocular lens for high primary and secondary hyperopia. J Refract Surg 2002; 18:697–707
86. Malecaze FJ, Hulin H, Bierer P, Fournié P, Grandjean H, Thalamas C, Guell JL. A randomized paired eye comparison of two techniques for treating moderately high myopia; LASIK and Artisan phakic lens. Ophthalmology 2002; 109:1622–1630
87. Fechner PU, Singh D, Wulff K. Iris-claw lens in phakic eyes to correct hyperopia: preliminary study. J Cataract Refract Surg 1998; 24:48–56
88. Worst JGF, van der Veen G, Los LI. Refractive surgery for high myopia; the Worst-Fechner biconcave iris claw lens. Doc Ophthalmol 1990; 75:335–341
89. Menezo JL, Aviño JA, Cisneros A, Rodriguez-Salvador V, Martinez-Costa R. Iris claw phakic intraocular lens for high myopia. J Refract Surg 1997; 13:545–555
90. Fechner PU, van der Heijde GL, Worst JGF. The correction of myopia by lens implantation into phakic eyes. Am J Ophthalmol 1989; 107:659–663
91. Fechner PU, Strobel J, Wichmann W. Correction of myopia by implantation of a concave Worst-iris claw lens into phakic eyes. Refract Corneal Surg 1991; 7:286–298
92. Menezo JL, Cisneros AL, Rodriguez-Salvador V. Endothelial study of iris-claw phakic lens: four year follow-up. J Cataract Refract Surg 1998; 24:1039–1049
93. Fechner PU, Wichmann W. Correction of myopia by implantation of minus optic (Worst iris claw) lenses into the anterior chamber of phakic eyes. Eur J Implant Refract Surg 1993; 5:55–59
94. Landesz M, Worst JGF, van Rij G. Long-term results of correction of high myopia with an iris claw phakic intraocular lens. J Refract Surg 2000; 16:310–316
95. Pérez-Santonja JJ, Bueno JL, Zato MA. Surgical correction of high myopia in phakic eyes with Worst-Fechner myopia intraocular lenses. J Refract Surg 1997; 13:268–281; discussion, 281–284
96. Menezo JL, Cisneros AL, Rodriguez-Salvador V. Removal of age-related cataract and iris claw phakic intraocular lens. J Refract Surg 1997; 13:589–590
97. Menezo JL, Cisneros AL, Cervera M, Harto M. Iris claw phakic lens—intermediate and long-term corneal endothelial changes. Eur J Implant Refract Surg 1994; 6:195–199
98. Saxena R, Landesz M, Noordzij B, Luyten GPM. Three-year follow-up of the Artisan phakic intraocular lens for hypermetropia. Ophthalmology 2003; 110:1391–1395
99. Menezo JL, Cisneros A, Hueso JR, Harto M. Long-term results of surgical treatment of high myopia with Worst-Fechner intraocular lenses. J Cataract Refract Surg 1995; 21:93–98
100. Asano-Kato N, Toda I, Hori-Komai Y, Sakai C, Fukumoto T, Arai H, Dogru M, Takano Y, Tsubota K. Experience with the Artisan phakic intraocular lens in Asian eyes. J Cataract Refract Surg 2005; 31:910–915
101. Baïkoff G, Bourgeon G, Jodai HJ, Fontaine A, Viera Lellis F, Trinquet L. Pigment dispersion and Artisan phakic intraocular lenses; crystalline lens rise as a safety criterion. J Cataract Refract Surg 2005; 31:674–680
102. Benedetti S, Casamenti V, Marcaccio L, Brogioni C, Assetto V. Correction of myopia of 7 to 24 diopters with the Artisan phakic intraocular lens: two-year follow-up. J Refract Surg 2005; 21:116–126
103. Muñoz G, Alió JL, Montés-Micó R, Albarrán-Diego C, Belda JI. Artisan iris-claw phakic intraocular lens followed by laser in situ keratomileusis for high hyperopia. J Cataract Refract Surg 2005; 31:308–317
104. Lombardo AJ, Hardten DR, McCulloch AG, Demarchi JL, Davis EA, Lindstrom RL. Changes in contrast sensitivity after Artisan lens implantation for high myopia. Ophthalmology 2005; 112:278–285
105. Lifshitz T, Levy J, Aizenman I, Klemperer I, Levinger S. Artisan phakic intraocular lens for correcting high myopia. Int Ophthalmol 2004; 25:233–238
106. Chandhrasri S, Knorz MC. Comparison of higher order aberrations and contrast sensitivity after LASIK, Verisyse phakic IOL, and Array multifocal IOL. J Refract Surg 2006; 22: 231–236
107. Senthil S, Reddy KP. A retrospective analysis of the first Indian experience on Artisan phakic intraocular lens. Indian J Ophthalmol 2006; 54:251–255. Available at: http://www.ijo.in/temp/IndianJOphthalmol544251_084330.pdf. Accessed April 13, 2008
108. Ertürk H, Özçetin H. Phakic posterior chamber intraocular lenses for the correction of high myopia. J Refract Surg 1995; 11:388–391
109. Brauweiler PH, Wehler T, Busin M. High incidence of cataract formation after implantation of a silicone posterior chamber lens in phakic, highly myopic eyes. Ophthalmology 1999; 106:1651–1655
110. Pesando PM, Ghiringhello MP, Tagliavacche P. Posterior chamber Collamer phakic intraocular lens for myopia and hyperopia. J Refract Surg 1999; 15:415–423
111. Trindade F, Pereira F, Cronemberger S. Ultrasound biomicroscopic imaging of posterior chamber phakic intraocular lens. J Refract Surg 1998; 14:497–503
112. Menezo JL, Peris-Martínez C, Cisneros A, Martínez-Costa R. Posterior chamber phakic intraocular lenses to correct high myopia: a comparative study between Staar and Adatomed models. J Refract Surg 2001; 17:32–42
113. Rosen E, Gore C. Staar Collamer posterior chamber phakic intraocular lens to correct myopia and hyperopia. J Cataract Refract Surg 1998; 24:596–606
114. Davidorf JM, Zaldivar R, Oscherow S. Posterior chamber phakic intraocular lens for hyperopia of +4 to +11 diopters. J Refract Surg 1998; 14:306–311
115. Zaldivar R, Davidorf JM, Oscherow S. Posterior chamber phakic intraocular lens for myopia of −8 to −19 diopters. J Refract Surg 1998; 14:294–305
116. Zaldivar R, Davidorf JM, Oscherow S, Ricur G, Piezzi V. Combined posterior chamber phakic intraocular lens and laser in situ keratomileusis: bioptics for extreme myopia. J Refract Surg 1999; 15:299–308
117. Sánchez-Galeana CA, Smith RJ, Rodriguez X, Montes M, Chayet AS. Laser in situ keratomileusis and photorefractive keratectomy for residual refractive error after phakic intraocular lens implantation. J Refract Surg 2001; 17:299–304
118. Kaya V, Kevser MA, Yilmaz ÖF. Phakic posterior chamber plate intraocular lenses for high myopia. J Refract Surg 1999; 15:580–585
119. Lesueur LC, Arne JL. Phakic posterior chamber lens implantation in children with high myopia. J Cataract Refract Surg 1999; 25:1571–1575
120. Bloomenstein MR, Dulaney DD, Barnet RW, Perkins SA. Posterior chamber phakic intraocular lens for moderate myopia and hyperopia. Optometry 2002; 73:435–446
121. Dejaco-Ruhswurm I, Scholz U, Pieh S, Hanselmayer G, Lackner B, Italon C, Ploner M, Skorpik C. Long-term

endothelial changes in phakic eyes with posterior chamber intraocular lenses. J Cataract Refract Surg 2002; 28:1589–1593
122. Gonvers M, Othenin-Girard P, Bornet C, Sickenberg M. Implantable contact lens for moderate to high myopia; short-term follow-up of 2 models. J Cataract Refract Surg 2001; 27:380–388
123. Marinho A, Neves MC, Pinto MC, Vaz F. Posterior chamber silicone phakic intraocular lens. J Refract Surg 1997; 13:219–222
124. Arne JL, Lesueur LC, Hulin HH. Photorefractive keratectomy or laser in situ keratomileusis for residual refractive error after phakic intraocular lens implantation. J Cataract Refract Surg 2003; 29:1167–1173
125. Abela-Formanek C, Kruger AJ, Dejaco-Ruhswurm I, Pieh S, Skorpik C. Gonioscopic changes after implantation of a posterior chamber lens in phakic myopic eyes. J Cataract Refract Surg 2001; 27:1919–1925
126. Trindade F, Pereira F. Cataract formation after posterior chamber phakic intraocular lens implantation. J Cataract Refract Surg 1998; 24:1661–1663
127. Fink AM, Gore C, Rosen E. Cataract development after implantation of the Staar Collamer posterior chamber phakic lens. J Cataract Refract Surg 1999; 25:278–282
128. Implantable Contact Lens in Treatment of Myopia (ITM) Study Group. U.S. Food and Drug Administration clinical trial of the implantable contact lens for moderate to high myopia. Ophthalmology 2003; 110:255–266
129. Gonvers M, Bornet C, Othenin-Girard P. Implantable contact lens for moderate to high myopia; relationship of vaulting to cataract formation. J Cataract Refract Surg 2003; 29: 918–924
130. Lesueur LC, Arne JL. Phakic intraocular lens to correct high myopic amblyopia in children. J Refract Surg 2002; 18:519–523
131. Arne JL. Phakic intraocular lens implantation versus clear lens extraction in highly myopic eyes of 30- to 50-year-old patients. J Cataract Refract Surg 2004; 30:2092–2096
132. Pineda-Fernández A, Jaramillo J, Vargas J, Jaramillo M, Jaramillo J, Galíndez A. Phakic posterior chamber intraocular lens for high myopia. J Cataract Refract Surg 2004; 30:2277–2283
133. García-Feijoó J, Hernández-Matamoros JL, Castillo-Gómez A, Méndez-Hernández C, Martínez de la Casa JM, Martín Orte T, García-Sanchez J. Secondary glaucoma and severe endothelial damage after silicone phakic posterior chamber intraocular lens implantation. J Cataract Refract Surg 2004; 30:1786–1789
134. Lackner B, Pieh S, Schmidinger G, Hanselmayer G, Dejaco-Ruhswurm I, Funovics MA, Skorpik C. Outcome after treatment of ametropia with implantable contact lenses. Ophthalmology 2003; 110:2153–2161
135. Lackner B, Pieh S, Schmidinger G, Simader C, Franz C, Dejaco-Ruhswurm I, Skorpik C. Long-term results of implantation of phakic posterior chamber intraocular lenses. J Cataract Refract Surg 2004; 30:2269–2276
136. Sanders DRICL in Treatment of Myopia (ITM) Study Group. Postoperative inflammation after implantation of the Implantable Contact Lens for the. Ophthalmology 2003; 110:2335–2341
137. Shen Y, Du C, Gu Y, Wang J. Posterior chamber phakic intraocular lens implantation for high myopia. Chin Med J 2003; 116:1523–1526. Available at: http://www.cmj.org/Periodical/PDF/2003/2003101523.pdf. Accessed April 13, 2008
138. Arne JL, Lesueur LC. Phakic posterior chamber lenses for high myopia: functional and anatomical outcomes. J Cataract Refract Surg 2000; 26:369–374
139. García-Feijoó J, Hernández-Matamoros JL, Méndez-Hernández C, Castillo-Goméz A, Lázaro C, Martín T, Cuiña-Sardiña R, García-Sánchez J. Ultrasound biomicroscopy of silicone posterior chamber phakic intraocular lens for myopia. J Cataract Refract Surg 2003; 29:1932–1939
140. Bleckmann H, Keuch RJ. Results of cataract extraction after implantable contact lens removal. J Cataract Refract Surg 2005; 31:2329–2333
141. Sarikkola A-U, Sen HN, Uusitalo RJ, Laatikainen L. Traumatic cataract and other adverse events with the implantable contact lens. J Cataract Refract Surg 2005; 31:511–524
142. Jongsareejit A. Clinical results with the Medennium phakic refractive lens for the correction of high myopia. J Refract Surg 2006; 22:890–897
143. Sarver EJ, Sanders DR, Vukich JA. Image quality in myopic eyes corrected with laser in situ keratomileusis and phakic intraocular lens. J Refract Surg 2003; 19:397–404
144. Rodriguez A, Gutierrez E, Alvira G. Complications of clear lens extraction in axial myopia. Arch Ophthalmol 1987; 105:1522–1523
145. Waring GO III. Comparison of refractive corneal surgery and phakic IOLs [editorial]. J Refract Surg 1998; 14:277–279
146. García M, González C, Pascual I, Fimia A. Magnification and visual acuity in highly myopic phakic eyes corrected with an anterior chamber intraocular lens versus by other methods. J Cataract Refract Surg 1996; 22:1416–1422
147. Koch DD. Enter with caution [editorial]. J Cataract Refract Surg 1996; 22:153–154
148. Gimbel HV, Ziémba SL. Management of myopic astigmatism with phakic intraocular lens implantation. J Cataract Refract Surg 2002; 28:883–886
149. Alió JL, Galal A, Mulet ME. Surgical correction of high degrees of astigmatism with a phakic toric-iris claw intraocular lens. Int Ophthalmol Clin 2003; 43(3):171–181
150. Visessook N, Peng Q, Apple DJ, Geri R, Schmickler S, Schoderbek RJ Jr, Guindi A. Pathological examination of an explanted phakic posterior chamber intraocular lens. J Cataract Refract Surg 1999; 25:216–222
151. Kelman C. Phakic intraocular lenses. Are the sirens singing again? [editorial] J Refract Surg 1998; 14:273–274
152. van der Heijde GL. Some optical aspects of implantation of an IOL in a myopic eye. Eur J Implant Refract Surg 1989; 1: 245–248
153. Wiechens B, Winter M, Haigis W, Happe W, Behrendt S, Rochels R. Bilateral cataract after phakic posterior chamber top hat-style silicone intraocular lens. J Refract Surg 1997; 13:392–397
154. Werner L, Izak AM, Pandey SK, Apple DJ, Trivedi RH, Schmidbauer JM. Correlation between different measurements within the eye relative to phakic intraocular lens implantation. J Cataract Refract Surg 2004; 30:1982–1988
155. Vetrugno M, Cardascia N, Cardia L. Anterior chamber depth measured by two methods in myopic and hyperopic phakic IOL implant. Br J Ophthalmol 2000; 84:1113–1116
156. Fechner PU. Cataract formation with a phakic IOL [letter]. J Cataract Refract Surg 1999; 25:461–462
157. Morales AJ, Zadok D, Tardio E, Anzoulatous G Jr, Litwak S, Mora R, Martinez E, Chayet AS. Outcome of simultaneous phakic implantable contact lens removal with cataract extraction and pseudophakic intraocular lens implantation. J Cataract Refract Surg 2006; 32:595–598
158. Pop M, Payette Y, Mansour M. Predicting sulcus size using ocular measurements. J Cataract Refract Surg 2001; 27:1033–1038
159. Pop M, Payette Y, Mansour M. Ultrasound biomicroscopy of the Artisan phakic intraocular lens in hyperopic eyes. J Cataract Refract Surg 2002; 28:1799–1803

160. Pop M, Mansour M, Payette Y. Ultrasound biomicroscopy of the iris-claw phakic intraocular lens for high myopia. J Refract Surg 1999; 15:632–635
161. Ferreira de Souza R, Allemann N, Forseto A, Moraes Barros PS, Chamon W, Nosé W. Ultrasound biomicroscopy and Scheimpflug photography of angle-supported phakic intraocular lens for high myopia. J Cataract Refract Surg 2003; 29:1159–1166
162. Trindade F, Pereira F. Exchange of a posterior chamber phakic intraocular lens in a highly myopic eye. J Cataract Refract Surg 2000; 26:773–776
163. Kim DY, Reinstein DZ, Silverman RH, Najafi DJ, Belmont SC, Hatsis AP, Rozakis GW, Coleman DJ. Very high frequency ultrasound analysis of a new phakic posterior chamber intraocular lens in situ. Am J Ophthalmol 1998; 125:725–729
164. Baïkoff G. Anterior segment OCT and phakic intraocular lenses: a perspective. J Cataract Refract Surg 2006; 32:1827–1835
165. Chipont EM, García-Hermosa P, Alió JL. Reversal of myopic anisometropic amblyopia with phakic intraocular lens implantation. J Refract Surg 2001; 17:460–462
166. Saxena R, van Minderhout HM, Luyten GPM. Anterior chamber iris-fixated phakic intraocular lens for anisometropic amblyopia. J Cataract Refract Surg 2003; 29:835–838
167. Baikoff G, Colin J. Intraocular lenses in phakic patients. Ophthalmol Clin North Am 1992; 5(4):789–795
168. Hoffer KJ. Pigment vacuum iridectomy for phakic refractive lens implantation. J Cataract Refract Surg 2001; 27:1166–1168
169. Chylack LT Jr, Wolfe JK, Singer DM, Leske MC, Bullimore MA, Bailey IL, Friend J, McCarthy D, Wu SY. The Lens Opacities Classification System III; the Longitudinal Study of Cataract Study Group. Arch Ophthalmol 1993; 111:831–836
170. Chylack LT Jr, Leske MC, McCarthy D, Khu P, Kashiwagi T, Sperduto R. Lens Opacities Classification System II (LOCS II). Arch Ophthalmol 1989; 107:991–997
171. Metge P, Pichot de Champfleury A. La cataracte du myope fort. In: Mondon H, Metge P, eds, La Myopie Forte. Paris, France, Masson, 1994; 447–465
172. Muñoz G, Montés-Micó R, Belda JI, Alió JL. Cataract after minor trauma in a young patient with an iris-fixated intraocular lens for high myopia. Am J Ophthalmol 2003; 135:890–891
173. Kohnen T, Baumeister M, Magdowski G. Scanning electron microscopic characteristics of phakic intraocular lenses. Ophthalmology 2000; 107:934–939
174. Hardten DR. Phakic iris claw artisan intraocular lens for correction of high myopia and hyperopia. Int Ophthalmol Clin 2000; 40(3):209–221
175. Maldonado MJ, García-Feijoó J, Benítez Del Castillo JM, Teutsch P. Cataractous changes due to posterior chamber flattening with a posterior chamber phakic intraocular lens secondary to the administration of pilocarpine. Ophthalmology 2006; 113:1283–1288
176. Kashani AA. Phakic posterior chamber intraocular lenses for the correction of high myopia. J Refract Surg 1996; 12: 454–456
177. Bechmann M, Ullrich S, Thiel MJ, Kenyon KR, Ludwig K. Imaging of posterior chamber phakic intraocular lens by optical coherence tomography. J Cataract Refract Surg 2002; 28: 360–363
178. Zaldivar R, Oscherow S, Ricur G. The STAAR posterior chamber phakic intraocular lens. Int Ophthalmol Clin 2000; 40(3):237–244
179. Arné J-L, Hoang-Xuan T. Posterior chamber phakic intraocular lenses. In: Azar DT, ed, Intraocular Lenses in Cataract and Refractive Surgery. Philadelphia, PA, WB Saunders, 2001; 267–272
180. Apple DJ, Werner L. Complications of cataract and refractive surgery: a clinicopathological documentation discussion 107–109.. Trans Am Ophthalmol Soc 2001; 99:95–107. Available at: http://www.aosonline.org/xactions/1545-6110_v099_p095.pdf. Accessed April 13, 2008
181. Zadok D, Chayet A. Lens opacity after neodymium:YAG laser iridectomy for phakic intraocular lens implantation. J Cataract Refract Surg 1999; 25:592–593
182. Lim R, Mitchell P, Cumming RG. Refractive associations with cataract: the Blue Mountains Eye Study. Invest Ophthalmol Vis Sci 1999; 40:3021–3026. Available at: http://www.iovs.org/cgi/reprint/40/12/3021. Accessed April 13, 2008
183. Younan C, Mitchell P, Cumming RG, Rochtchina E, Wang JJ. Myopia and incident cataract and cataract surgery: the Blue Mountains Eye Study. Invest Ophthalmol Vis Sci 2002; 43:3625–3632. Available at: http://www.iovs.org/cgi/reprint/43/12/3625. Accessed April 13, 2008. Accessed April 17, 2008
184. Hoffer KJ. Ultrasound axial length measurement in biphakic eyes. J Cataract Refract Surg 2003; 29:961–965addendum to ultrasound axial length measurement in biphakic eyes: factors for Alcon L12500-L14000 anterior chamber phakic IOLs. J Cataract Refract Surg 2003; 32:751–752
185. Tahzib NG, Nuijts RM, Wu WY, Budo CJ. Long-term study of Artisan phakic intraocular lens implantation for the correction of moderate to high myopia; ten-year follow-up results. Ophthalmology 2007; 114:1133–1142